Mitral Stenosis

DEFINITION

- Mitral stenosis (MS), known in the literature since at least the 1669 description by John Mayow and a major manifestation of rheumatic heart disease (RHD), remains an important problem worldwide.
- While the developed world has all but eliminated RHD, it continues to be a major cause of heart disease, morbidity, and mortality in the low and middle-income countries (LMICs; 5.6 billion people or 80% of humanity), especially affecting children and young adults in their most productive age.
- Nonrheumatic MS is more difficult to diagnose and may need specialized treatment options.

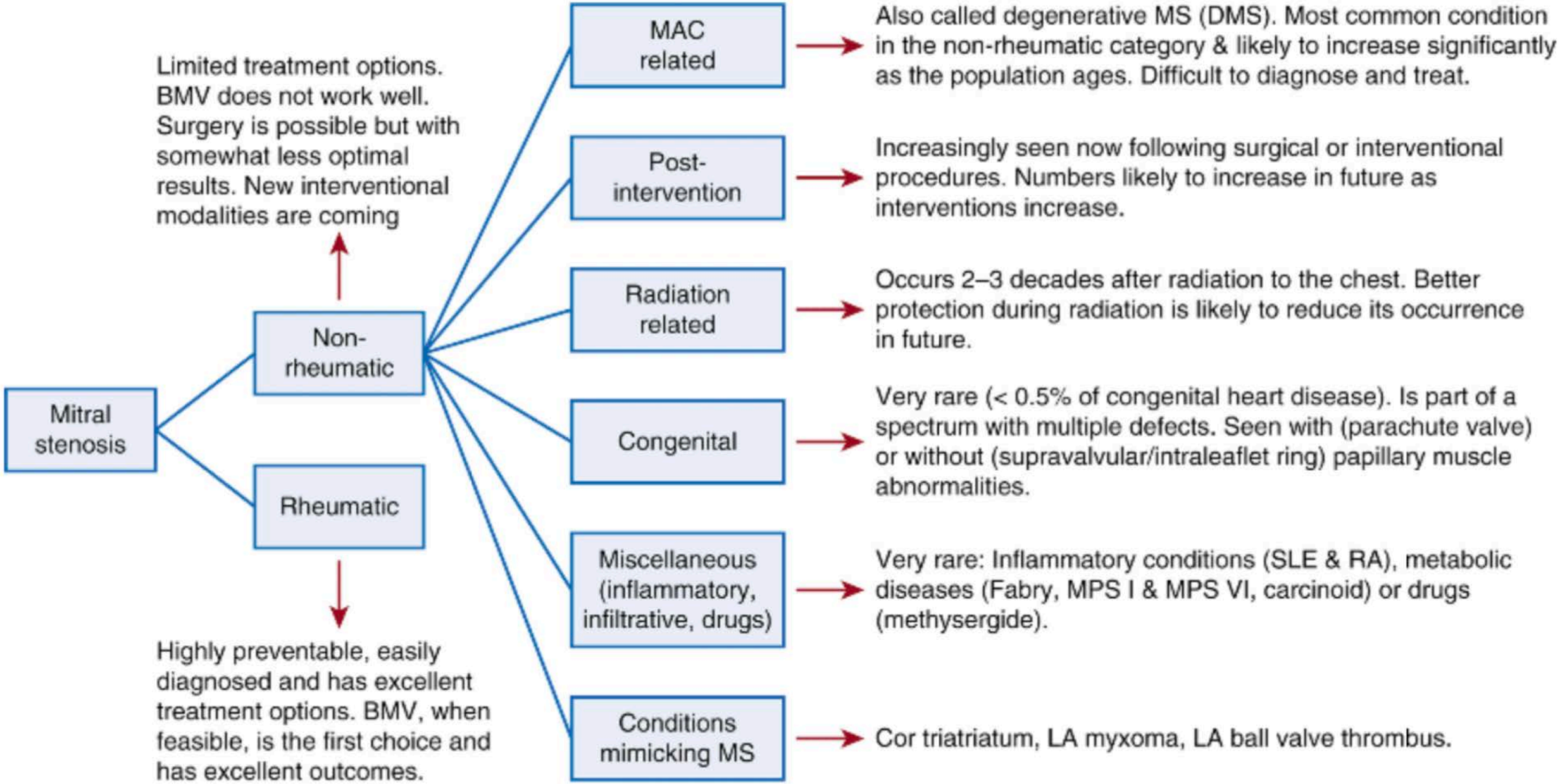
Mitral stenosis
Non-rheumatic
Rheumatic
Limited treatment options. BMV does not work well. Surgery is possible but with somewhat less optimal results. New interventional modalities are coming
Highly preventable, easily diagnosed and has excellent treatment options. BMV, when feasible, is the first choice and has excellent outcomes.
MAC related
Also called degenerative MS (DMS). Most common condition in the non-rheumatic category & likely to increase significantly as the population ages. Difficult to diagnose and treat.
Post-intervention
Increasingly seen now following surgical or interventional procedures. Numbers likely to increase in future as interventions increase.
Radiation related
Occurs 2–3 decades after radiation to the chest. Better protection during radiation is likely to reduce its occurrence in future.
Congenital
Very rare (< 0.5% of congenital heart disease). Is part of a spectrum with multiple defects. Seen with (parachute valve) or without (supravalvular/intraleaflet ring) papillary muscle abnormalities.
Miscellaneous (inflammatory, infiltrative, drugs)
Very rare: Inflammatory conditions (SLE & RA), metabolic diseases (Fabry, MPS I & MPS VI, carcinoid) or drugs (methysergide).
Conditions mimicking MS
Cor triatriatum, LA myxoma, LA ball valve thrombus.

Definition of Disease and Severity

- The normal mitral valve area (MVA) is ≥4.0 cm^2.
- A gradient across the mitral valve starts to form with reduction in MVA to 2.0 cm^2, considered mild MS, and symptoms begin to appear, initially with exercise.
- Symptoms, more consistently develop at ≤1.5 cm^2 and are associated with a 5 to 10 mm Hg gradient.
- Significant hemodynamic changes (gradients in excess of 10 mm Hg) and resting symptoms are common at MVA ≤1.0 cm^2.
- Guidelines consider “severe” MS based on when symptoms occur and where intervention can improve them, and ≤1.5 $cm^2$is the recommended threshold for this.

Pathology

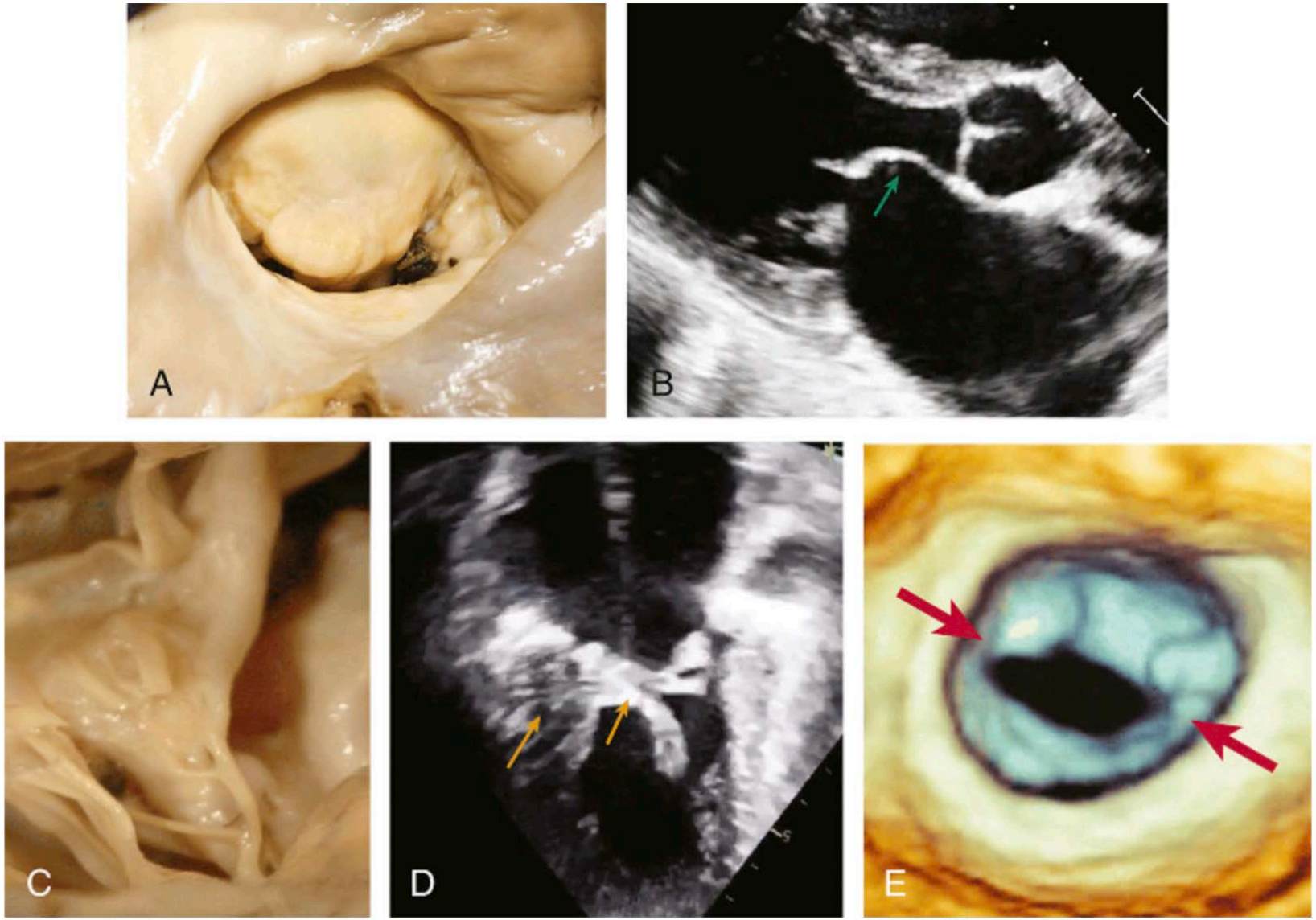

Clinical Pathophysiology: Left Atrial Pressure

- RMS is characterized by commissural fusion rather than just stiff valve leaflets and hence a relatively fixed orifice, and unlike AS, changes very little with varying hemodynamic conditions. An increased LA pressure is then needed to maintain left ventricular (LV) filling and preserve cardiac output.
- Tachycardia is one of the most important factors in increasing LA pressures since it significantly reduces diastolic filling time and compromises forward flow, which is immediately seen as high mitral valve gradients and worsening symptoms.
- Atrial contraction helps overcome the resistance at the mitral valve level and preserve forward flow in MS—not surprisingly, the loss of atrial contraction and tachycardia during atrial fibrillation (AF) can precipitate clinical worsening even in patients previously asymptomatic.
- Since the gradient across the mitral valve increases as a square of the flow, small increases in the latter can have large effects on the gradient and its resulting symptoms, as seen in pregnancy, severe anemia, thyrotoxicosis, systemic infection, and other hyperdynamic states.

Clinical Pathophysiology: Left Atrial Pressure

- Backward transmission of high LA pressures results in pulmonary venous hypertension and increased lung water; lung congestion explains exercise intolerance and dyspnea (and pulmonary edema in the most severe cases), and its relief, with diuretics or definitive MS treatment, is associated with immediate clinical benefit through reversing these changes.
- Some compensatory mechanisms alter the relationship between LA pressure increase and symptoms. Chronically elevated LA pressure results in alveolar/interstitial thickening that limits alveolar edema, and increased lymphatic drainage helps redistribute alveolar fluid.
- The development of PAH also ameliorates these symptoms but at the expense of right heart overload and possibly low cardiac output. Long-standing adverse changes in the lung and pulmonary vasculature can persist after relief of MS, explaining the lack of a direct relationship between hemodynamic improvement and changes in pulmonary function or exercise capacity.

Clinical Pathophysiology: Left Atrial Function

- LA function is variably affected depending on severity of MS and degree of fibrosis and can be a form of atrial myopathy. LA volume is increased and LA emptying fraction is reduced.

- Prolonged elevation of LA pressure and LA remodeling can result in LA fibrosis that affects LA compliance. This may not be reversible after BMV, and low net AV compliance, which reflects the LA-LV as a unit, predicts both need for intervention and worse prognosis after BMV.

Clinical Pathophysiology: Left Ventricular Function

- LV function is abnormal in some studies and is hypothesized to be due to multiple mechanisms (inflammatory process, tethering due to the rigid valve apparatus, altered LV compliance).

- However, it is not prominent in most patients with RMS but may be more prevalent in DMS due to coexisting comorbidities.

Clinical Pathophysiology: Right Ventricular Function

- Overt RV dysfunction occurs late in the course of MS and is often a consequence of PAH.
- RV enlargement and elevated PA pressures track the severity of MS.
- These findings convey adverse prognosis even in patients treated with Balloon Mitral Valvuloplasty or surgery.
- RV strain is emerging as a useful marker for subtle RV dysfunction even before onset of other signs, and it improves rapidly after Balloon Mitral Valvuloplasty.

Stenosi Mitralica
Fisiopatologia

Ostacolo al flusso di sangue a monte della stenosi

↓

Aumento di pressione in atrio sinistro

↓

Aumento di pressione nelle vene polmonari, nei capillari e nelle arterie polmonari

↓

Se la pressione>25-35 mmHg si verifica una trasudazione di liquido nell'interstizio polmonare

↓

Se non è drenato dall'apparato linfatico o è massivo: edema polmonare

Stenosi Mitralica
Fisiopatologia

Aumento delle resistenze arteriolari polmonari

Mantenimento della PAP

IA polmonare passiva o post-capillare

Aumento della PAP

IA polmonare reattiva

Aumento delle resistenze arteriolari polmonari

Sovraccarico di pressione sul ventricolo destro

Natural History

- Valve area in RMS decreases approximately 0.09 cm2 per year.
- Symptoms are an important trigger for definitive therapy and have strong prognostic value.
- Symptomatic patients with severe MS do poorly without intervention, with a mortality that varies from 8% to 13% per year in the first 5 years.
- Patients can first present with AF; almost 20% presented with an embolic episode in the past but early detection of AF in MS and aggressive use of oral anticoagulants (OACs) has markedly reduced this complication.

Diagnosis: Clinical Presentation

- Dyspnea, initially on exertion and then at rest, is the usual presentation in MS.
- Paroxysmal nocturnal dyspnea and orthopnea are seen in severe symptomatic MS but may become less common with longer duration of untreated illness, as compensatory mechanisms in the lung and pulmonary circulation attenuate alveolar edema.
- Onset of significant PAH, or aggressive use of diuretics and beta blockers, may reduce dyspnea but increase fatigue and symptoms of low cardiac output.
- Palpitations, often a consequence of AF, are seen in the later stages of the disease and increase with age.
- Pulmonary edema is now seen rarely.

Diagnosis: Physical Examination

- The former includes a loud S1 (and a tapping apex), the opening snap (OS), and mid-diastolic murmur with presystolic accentuation.
- The latter include the usual signs of AF, pulmonary venous and arterial hypertension, tricuspid regurgitation (TR), right heart failure, and, in late stages, systemic hypoperfusion.

Diagnosis: Echocardiography

- Echocardiography is the mainstay of diagnosis in all forms of MS it is the best modality to detect the presence and severity of LA outflow obstruction and evaluate its severity as well as hemodynamic consequences.
- Mitral Valvular Area is best assessed with planimetry.
- Gradients measured from Doppler tracings are reasonably accurate in reflecting the hemodynamic conditions.

Aspetto a doming dei lembi valvolari con evidenza di calcificazioni

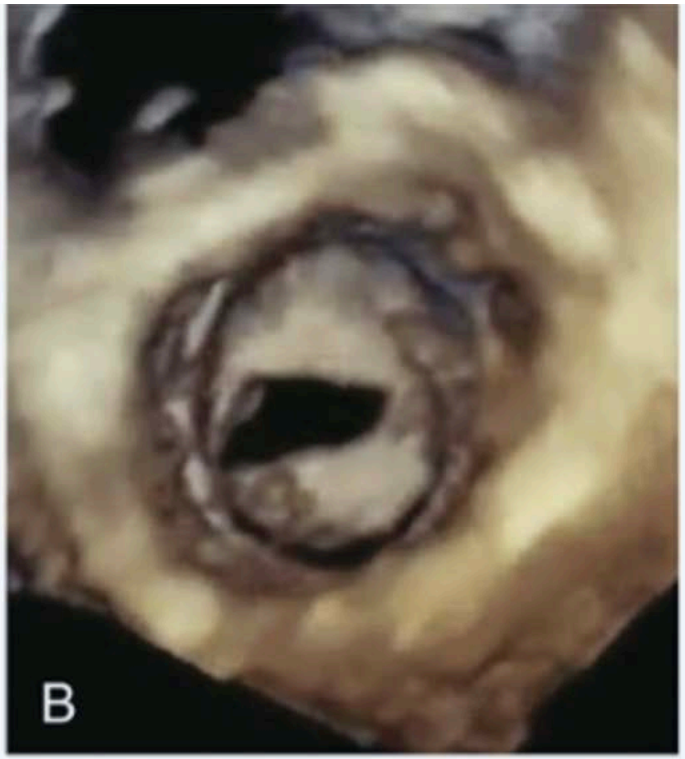

Aspetto caratteristico della stenosi al 3D a muso di pesce

Calcolo del PHT mediante Doppler: calcolo dei valori di area e gradiente pressorio per la severità della stenosi

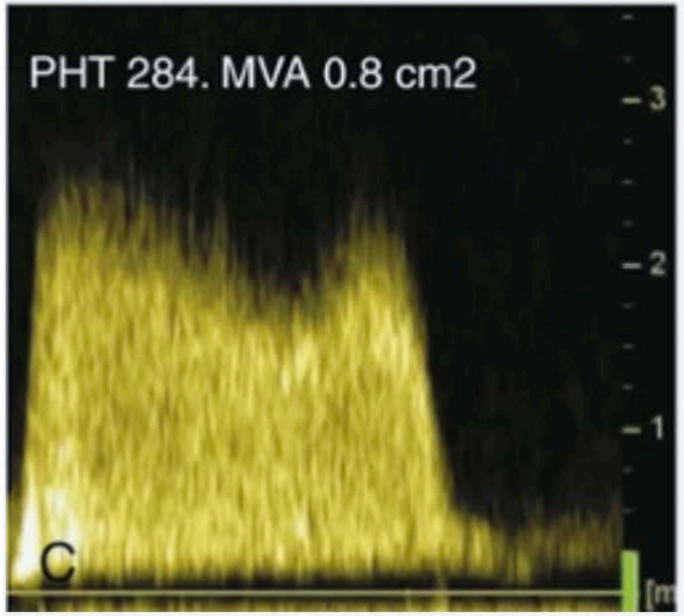

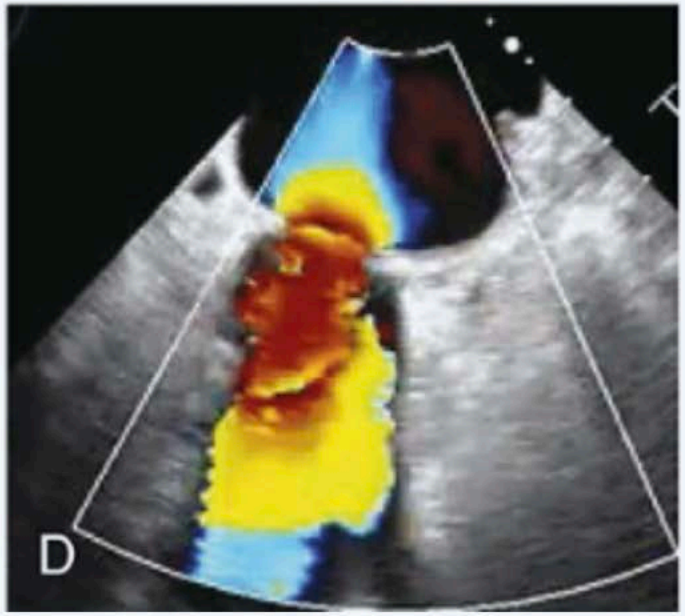

Turbolenza del flusso attraverso la stenosi valutata mediante Color

Diagnosis: Treatment

- Medical therapy does not change the progression of the disease but can be a reasonable temporary measure before definitive therapy and is also useful in some mildly symptomatic patients who are not yet candidates for definitive therapy or as a palliative measure in those not suitable for any intervention.

- Balloon Mitral Valvuloplasty is a very efficacious as well as cost effective treatment and is the preferred modality in most patients with valve area <1.5cm2 and suitable anatomy.

- Surgery is indicated in patients with contraindication for BMV, in those in whom BMV was unsuccessful, and in those with other conditions that would warrant surgery (TR, AS, or CAD).

Recommendations on indications for percutaneous mitral commissurotomy and mitral valve surgery in clinically significant (moderate or severe) mitral stenosis (valve area ≤1.5 cm^2) (1)

Recommendations	Class	Level
PMC is recommended in symptomatic patients without unfavourable characteristics for PMC.	I	B
PMC is recommended in any symptomatic patients with a contraindication or a high risk for surgery.	I	C
Mitral valve surgery is recommended in symptomatic patients who are not suitable for PMC in the absence of futility.	I	C

2021 ESC/EACTS Guidelines for the management of valvular heart disease
(European Heart Journal; 2021 – doi: 10.1093/eurheartj/ehab395; European Journal of Cardio-Thoracic Surgery; 2021 – doi: 10.1093/ejcts/ezab389)

Recommendations on indications for percutaneous mitral commissurotomy and mitral valve surgery in clinically significant (moderate or severe) mitral stenosis (valve area ≤1.5 cm^2) (2)

Recommendations	Class	Level
PMC should be considered as initial treatment in symptomatic patients with suboptimal anatomy but no unfavourable clinical characteristics for PMC.	IIa	C
PMC should be considered in asymptomatic patients without unfavourable clinical and anatomical characteristics* for PMC and: • High thromboembolic risk (history of systemic embolism, dense spontaneous contrast in the LA, new-onset or paroxysmal AF), and/or • High risk of haemodynamic decompensation (systolic pulmonary pressure >50 mmHg at rest, need for major NCS, desire for pregnancy).	IIa	C

** Unfavourable characteristics for PMC can be defined by the presence of several of the following characteristics. Clinical characteristics: old age, history of commissurotomy, New York Heart Association class IV, permanent AF, severe pulmonary hypertension. Anatomical characteristics: echocardiographic score >8, Cormier score 3 (calcification of mitral valve of any extent as assessed by fluoroscopy), very small MVA, severe tricuspid regurgitation.*

2021 ESC/EACTS Guidelines for the management of valvular heart disease
(European Heart Journal; 2021 – doi: 10.1093/eurheartj/ehab395; European Journal of Cardio-Thoracic Surgery; 2021 – doi: 10.1093/ejcts/ezab389)

Contraindications for percutaneous mitral commissurotomy in rheumatic mitral stenosis

Contraindications
MVA >1.5 cm^2*
LA thrombus
More than mild mitral regurgitation
Severe or bi-commissural calcification
Absence of commissural fusion
Severe concomitant aortic valve disease, or severe combined tricuspid stenosis and regurgitation requiring surgery
Concomitant CAD requiring bypass surgery

** PMC may be considered in patients with valve area >1.5 cm^2 with symptoms that cannot be explained by another cause and if the anatomy is favourable.*

2021 ESC/EACTS Guidelines for the management of valvular heart disease
(European Heart Journal; 2021 – doi: 10.1093/eurheartj/ehab395; European Journal of Cardio-Thoracic Surgery; 2021 – doi: 10.1093/ejcts/ezab389)

Multitrack Technique

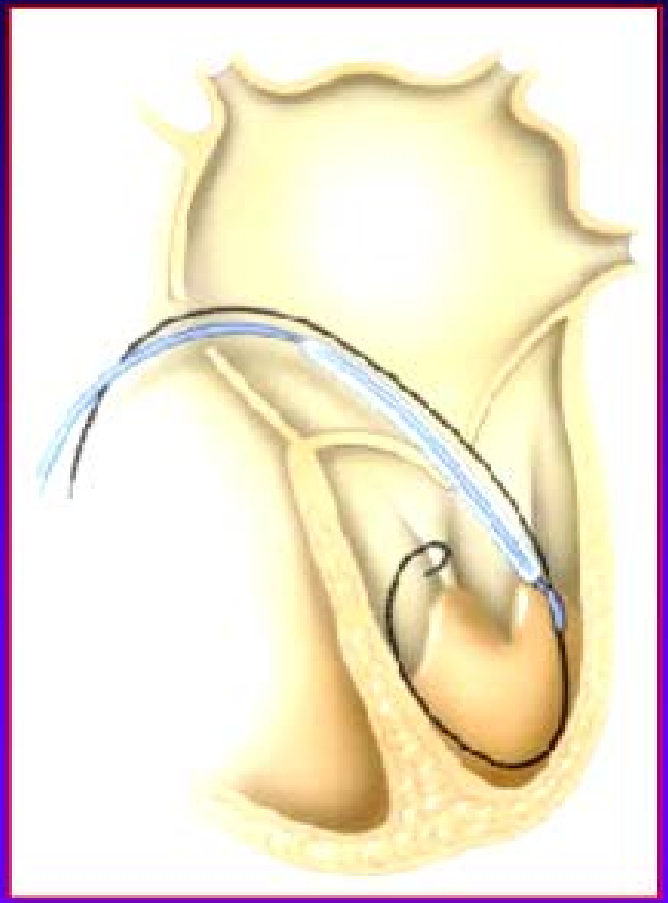

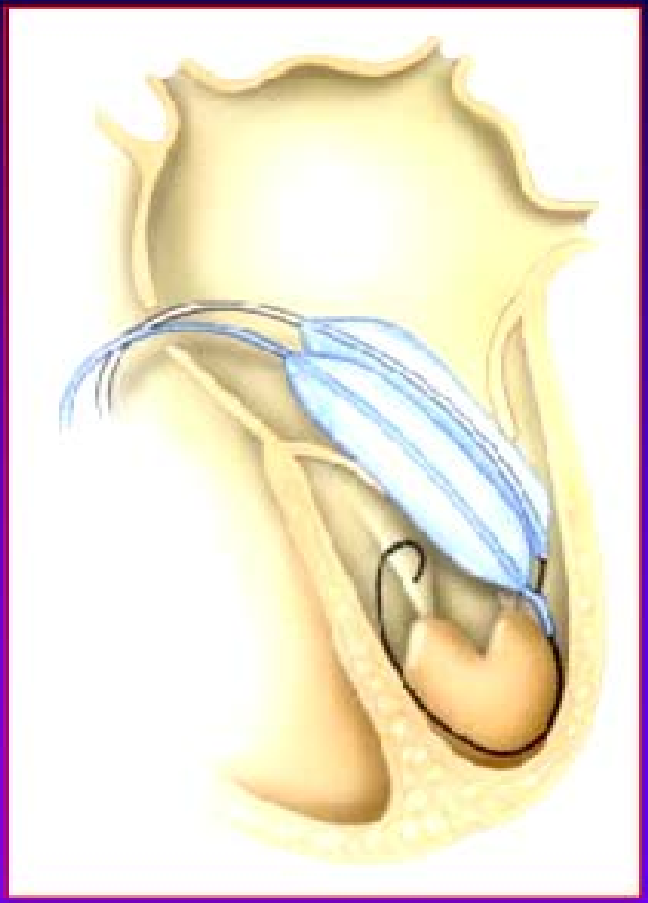



Mitral Regurgitation



Insufficienza Mitralica

DEFINIZIONE

Chiusura incompleta dell'ostio atrio-ventricolare di sinistra durante la sistole ventricolare. Ne risulta un reflusso sistolico di sangue dal ventricolo all’atrio sinistro.

In Europe, MR is the second most frequent valve disease requiring surgery.

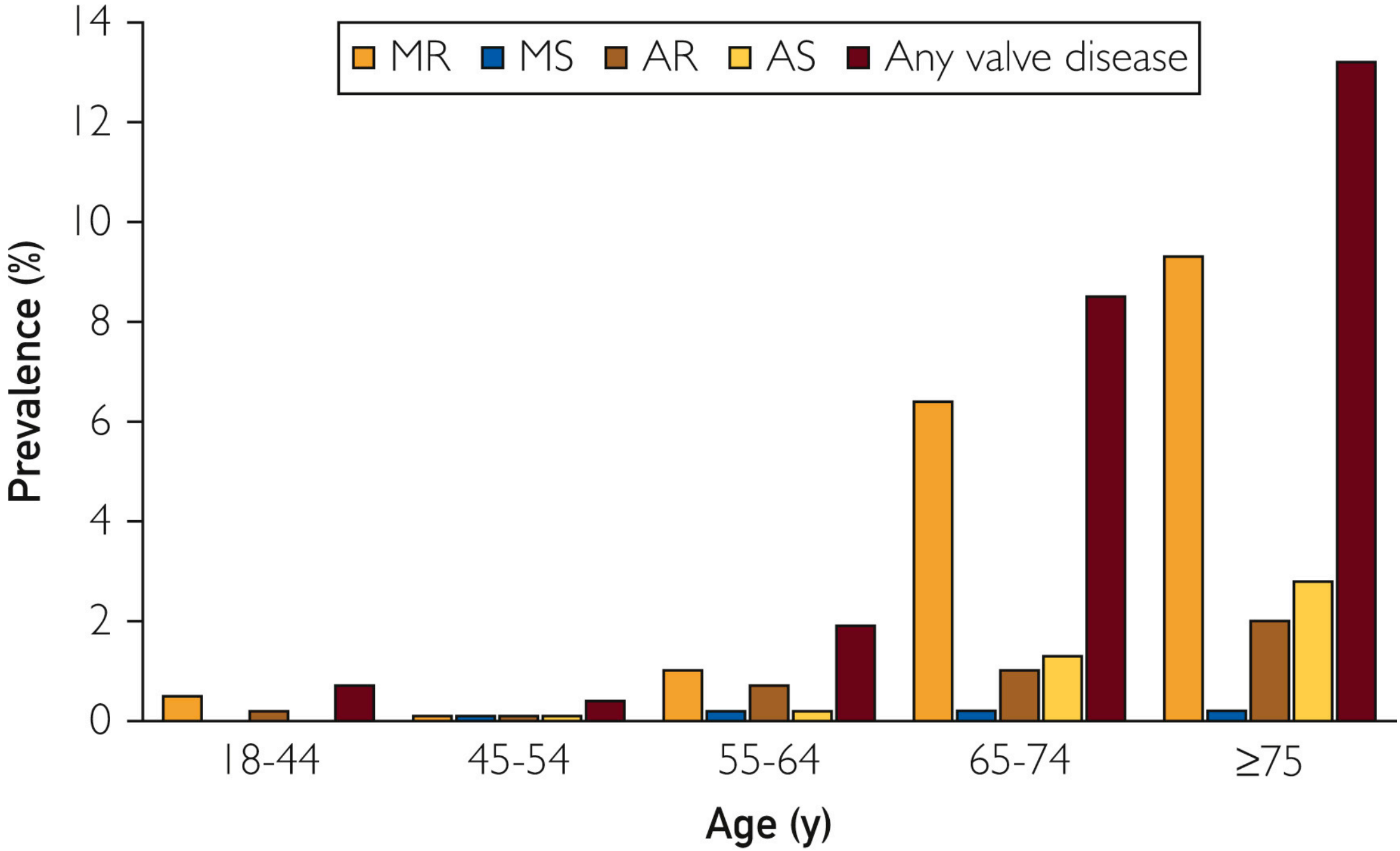
MR
MS
AR
AS
Any valve disease
Prevalence (%)
0
2
4
6
8
10
12
14
18-44
45-54
55-64
65-74
≥75
Age (y)

Apparato Valvolare Mitralico

È la corretta interazione fra anello valvolare, lembi valvolari, corde tendinee, muscoli papillari (anterolaterale e posteromediale) e ventricolo sinistro a far funzionare correttamente il meccanismo della valvola.

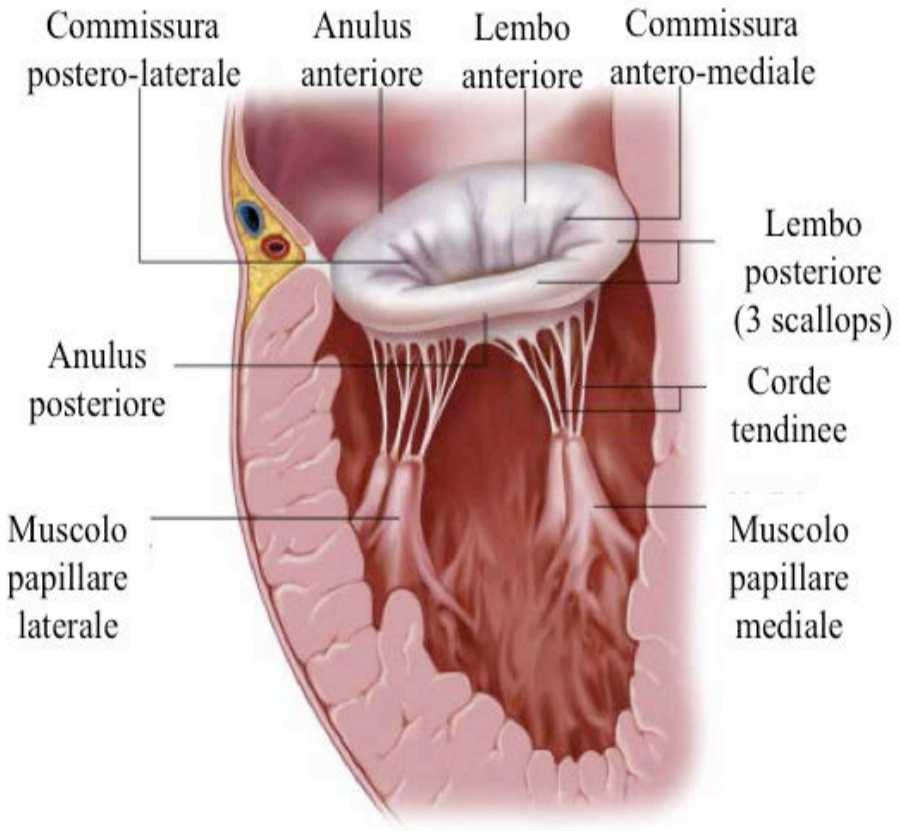

La valvola mitrale presenta due cuspidi: una, più grande, posta in avanti e medialmente e si chiama cuspide anteriore o aortica; l'altra, più piccola, posta indietro e lateralmente, che corrisponde alla parete posteriore del ventricolo sinistro e si chiama cuspide posteriore.

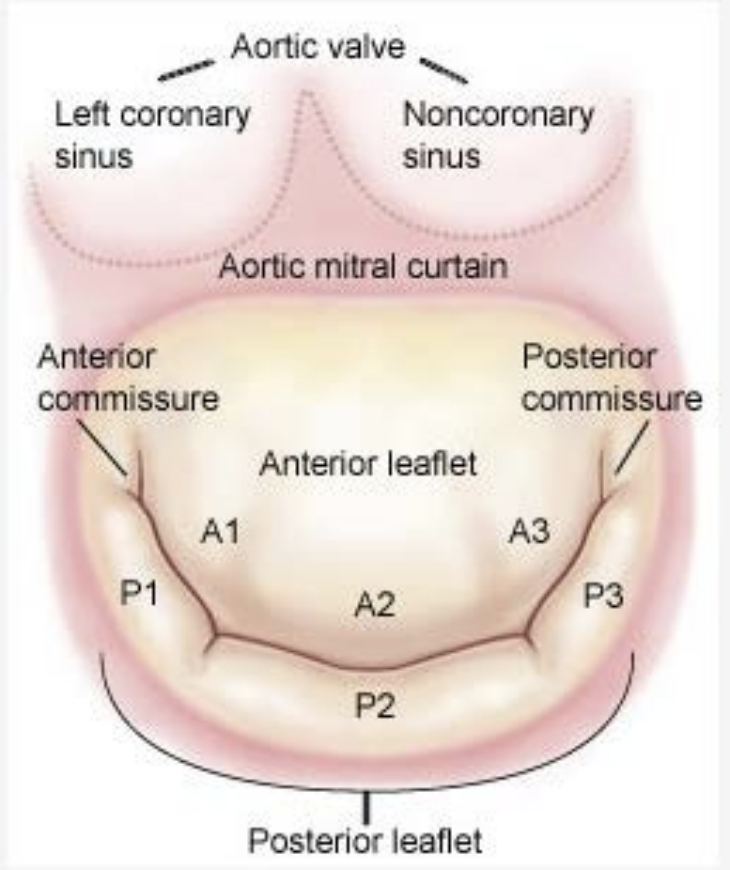

Classificazione dell’insufficienza mitralica

- **Degenerativa (o Primitiva): lesioni intrinseche della valvola, per esempio a prolasso valvolare mitralico, disordini del tessuto connettivo, degenerazione valvolare, radiazioni al torace.**
- **Funzionale (o Secondaria): valvola mitralica strutturalmente normale. È dovuta a cardiomiopatia dilatativa primitiva o post-ischemica (distorsione geometrica dell’apparato sottovalvolare), a fibrillazione atriale, a ipertensione arteriosa, a cardiomiopatie.**
- **Acuta: complicanze meccaniche di infarto o endocardite batterica.**

Classificazione di Carpentier

Dysfunction	Ventricular View	Atrial View	Etiologic Disorder
Type I Normal leaflet motion	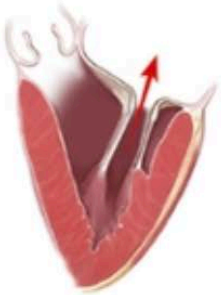		Ischemic cardiomyopathy Dilated cardiomyopathy Endocarditis Congenital
Type II Increased leaflet motion (leaflet prolapse)	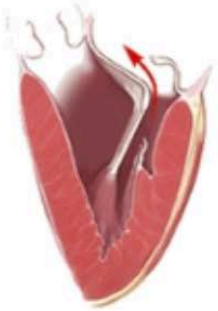	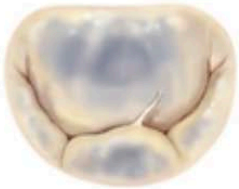	Degenerative disease Fibroelastic deficiency Marfan syndrome Forme fruste Barlow Barlow disease Endocarditis Rheumatic disease Trauma Ischemic cardiomyopathy Ehlers-Danlos syndrome
Type IIIA Restricted leaflet motion (restricted opening)			Rheumatic disease Carcinoid disease Radiation Lupus erythematosus Ergotamine use Hypereosinophilic syndrome Mucopolysaccharidosis
Type IIIB Restricted leaflet motion (restricted closure)	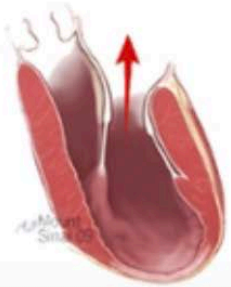		Ischemic cardiomyopathy Dilated cardiomyopathy

Dilatazione dell'anulus (tipo I)

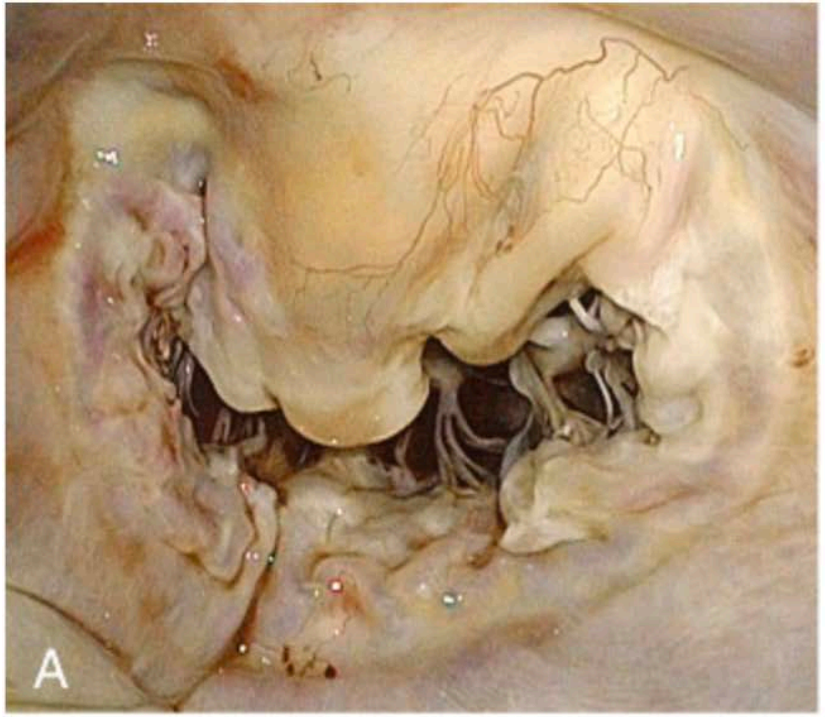

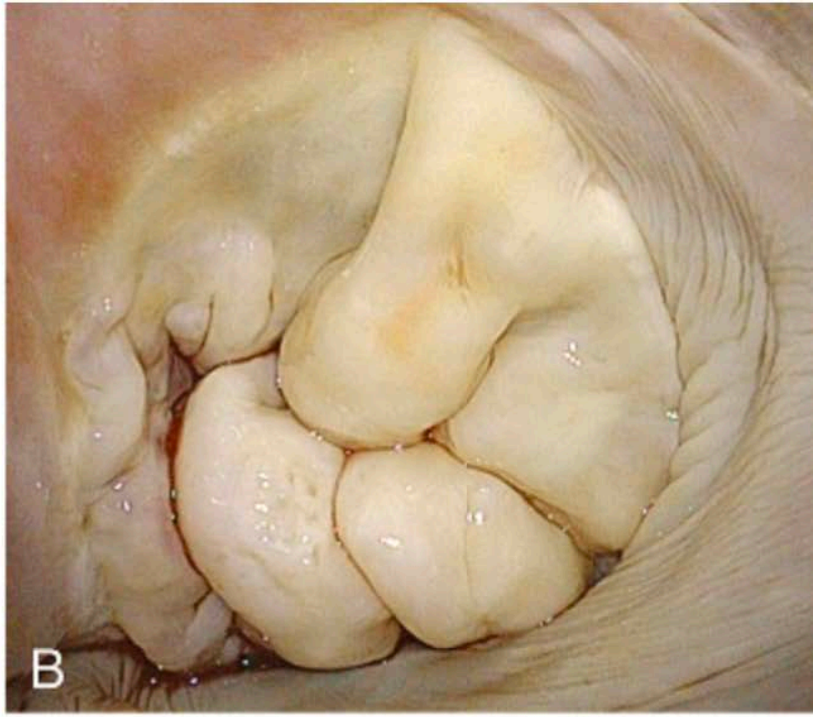

Degenerazione mixomatosa con prolasso (tipo II)

Mitrale reumatica: steno-insufficienza (tipo III A)

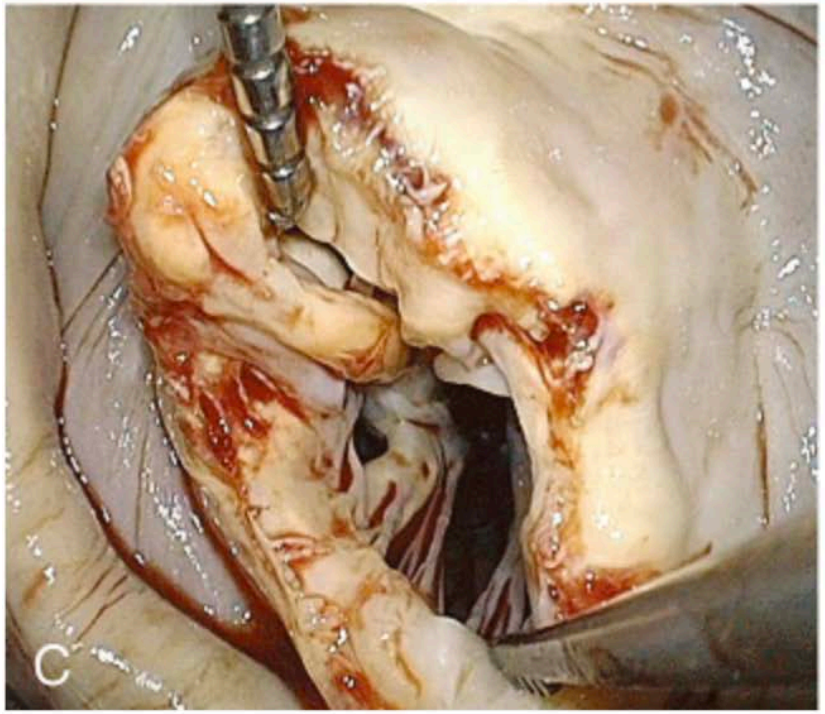

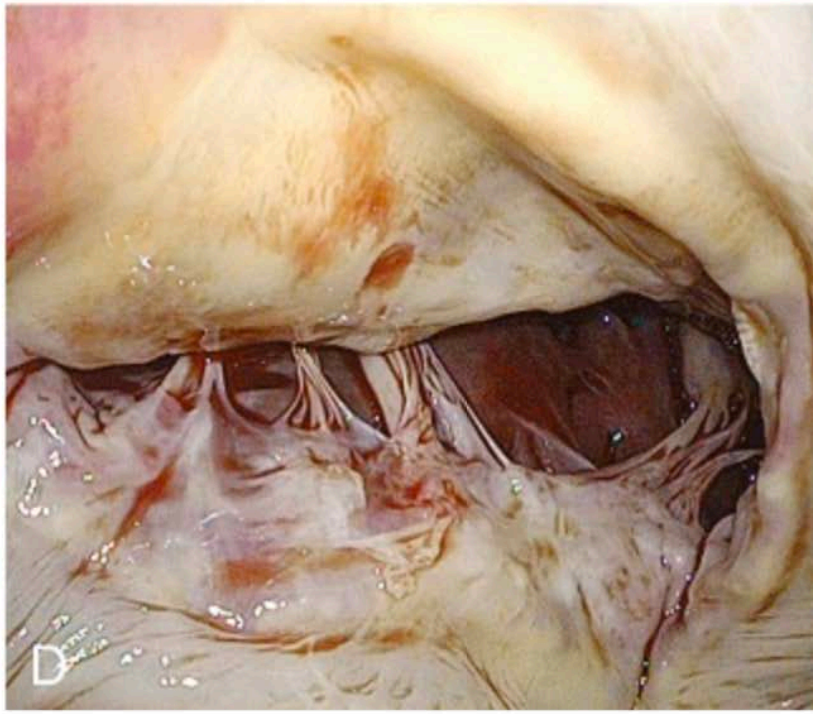

Mitrale isxchemica con tethering (spostamento verso il basso) di P3 (tipo III B)

Mitral Valve Regurgitation

Mitral Regurgitation

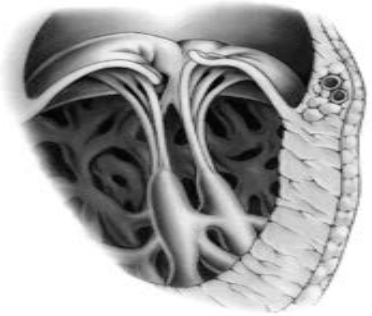

Mitral Regurgitation → Volume Overload → LV Disfunction → LV Dilatation

PRELOAD RESERVE AND AFTERLOAD MISMATCH

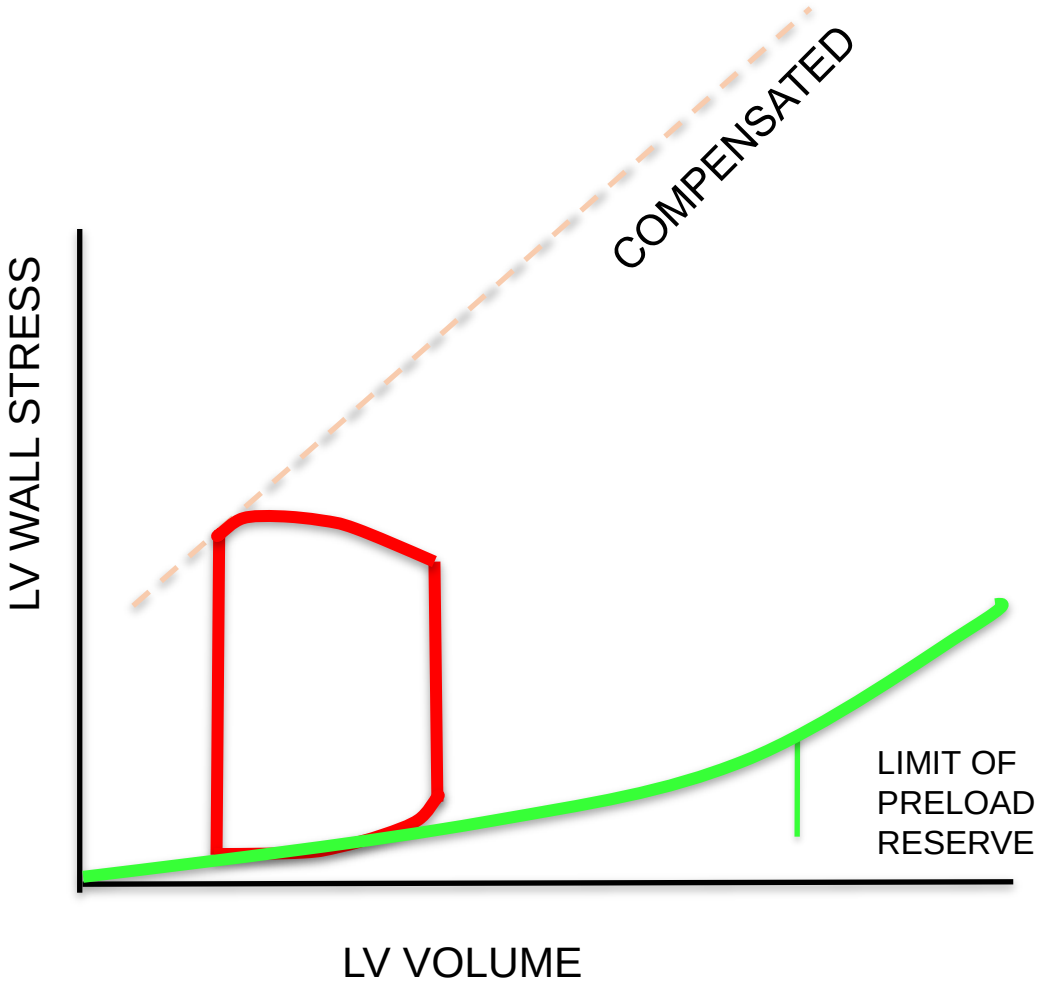
COMPENSATED
LV WALL STRESS
LIMIT OF
PRELOAD
RESERVE
LV VOLUME

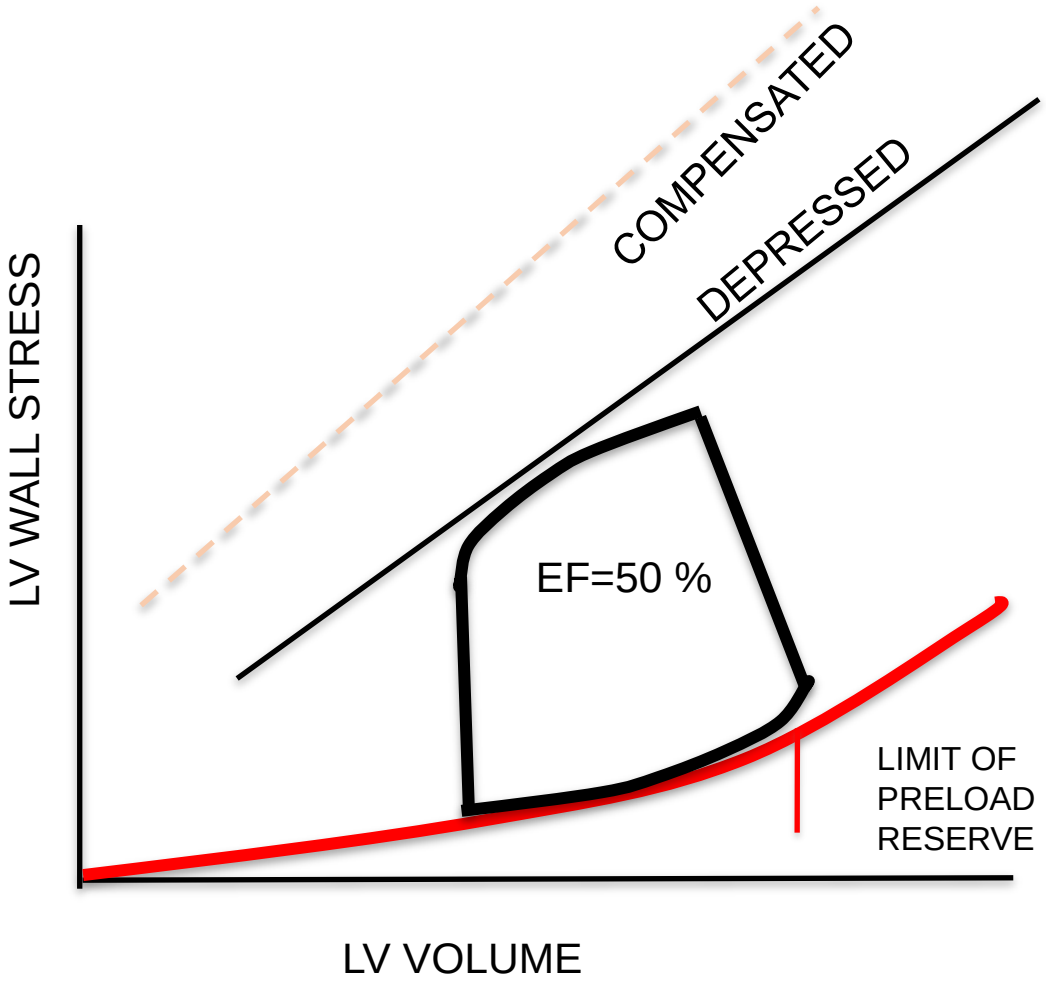
COMPENSATED
DEPRESSED
LV WALL STRESS
EF=50 %
LIMIT OF
PRELOAD
RESERVE
LV VOLUME

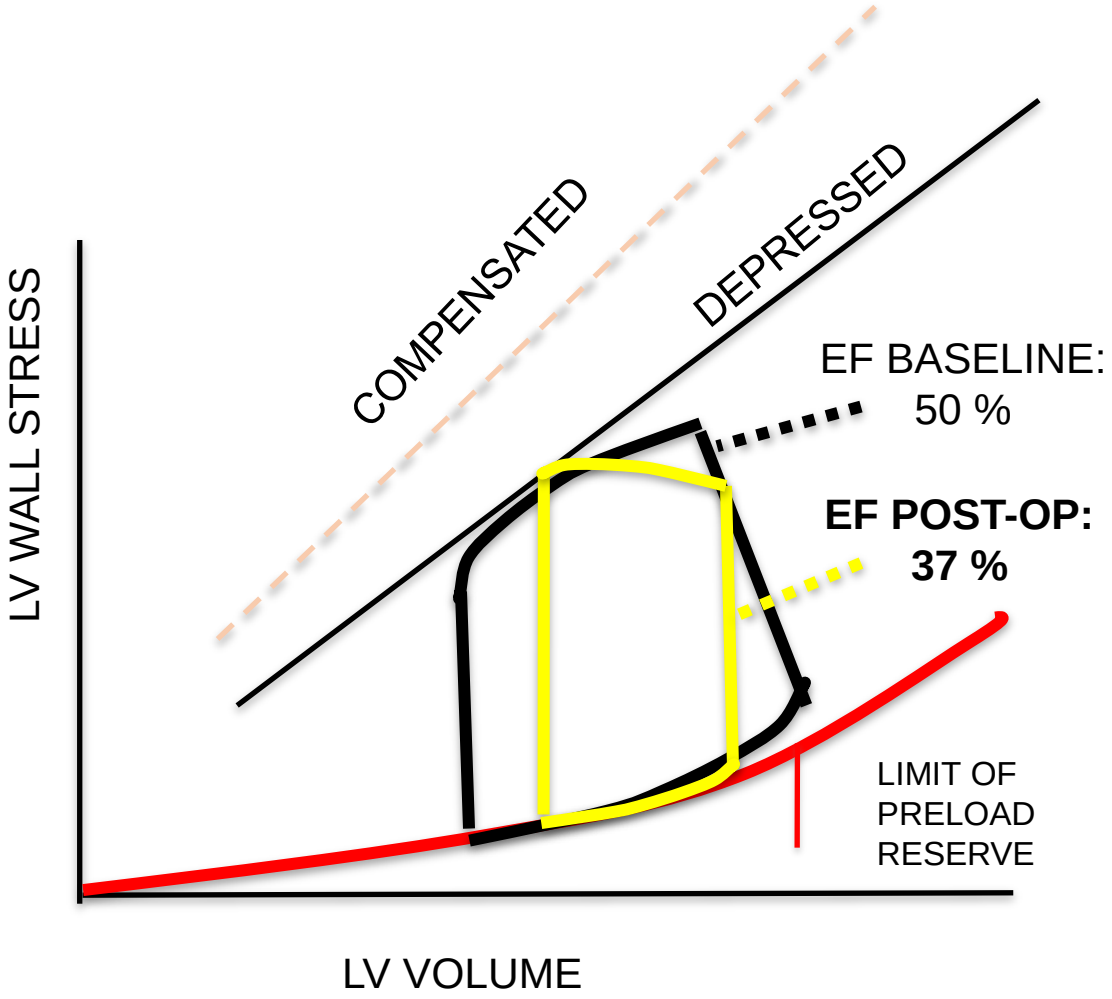
COMPENSATED
DEPRESSED
EF BASELINE:
50 %
EF POST-OP:
37 %
LIMIT OF
PRELOAD
RESERVE
LV WALL STRESS
LV VOLUME

Primary Mitral Regurgitation: Symptoms

- The nature and severity of symptoms in patients with chronic MR are functions of a combination of interrelated factors, including the severity of MR, rate of its progression, level of LA, pulmonary venous, and pulmonary arterial (PA) pressure, presence of episodic or chronic atrial tachyarrhythmias, and presence of associated valvular, myocardial, or coronary artery disease.
- In addition, there may be symptoms related to the underlying pathogenic cause of the MR (e.g., endocarditis, lupus, or Marfan syndrome).
- Many patients with severe MR remain completely asymptomatic.

Primary Mitral Regurgitation: Diagnosis

- Echocardiography plays an integral role in the diagnosis of primary MR, in determining its cause and potential for repair, and in quantifying its severity. Assessment of MR severity by echocardiography can be divided into four general categories: structural, qualitative, semi-quantitative, and quantitative.
- Structural assessment of patients with severe MR, includes not only the determination of valve morphology and mechanisms of MR, but should also provide measures of LV systolic function, severity of dilation of the LV and LA, and right heart size and function.
- Quantification of mitral leaflet lengths, severity of tethering, and the severity of leaflet displacement into the atrium may be important for determining the success of surgical or transcatheter interventions.
- Semi-quantitative assessment of MR severity include measurements of components of the color Doppler regurgitant jet: flow convergence, jet width at the vena contracta, and jet area.
- Quantitative methods to measure regurgitant fraction, regurgitant volume (Rvol), and regurgitant orifice area have greater accuracy when done carefully, and these methods are strongly recommended.

Primary Mitral Regurgitation: Diagnosis

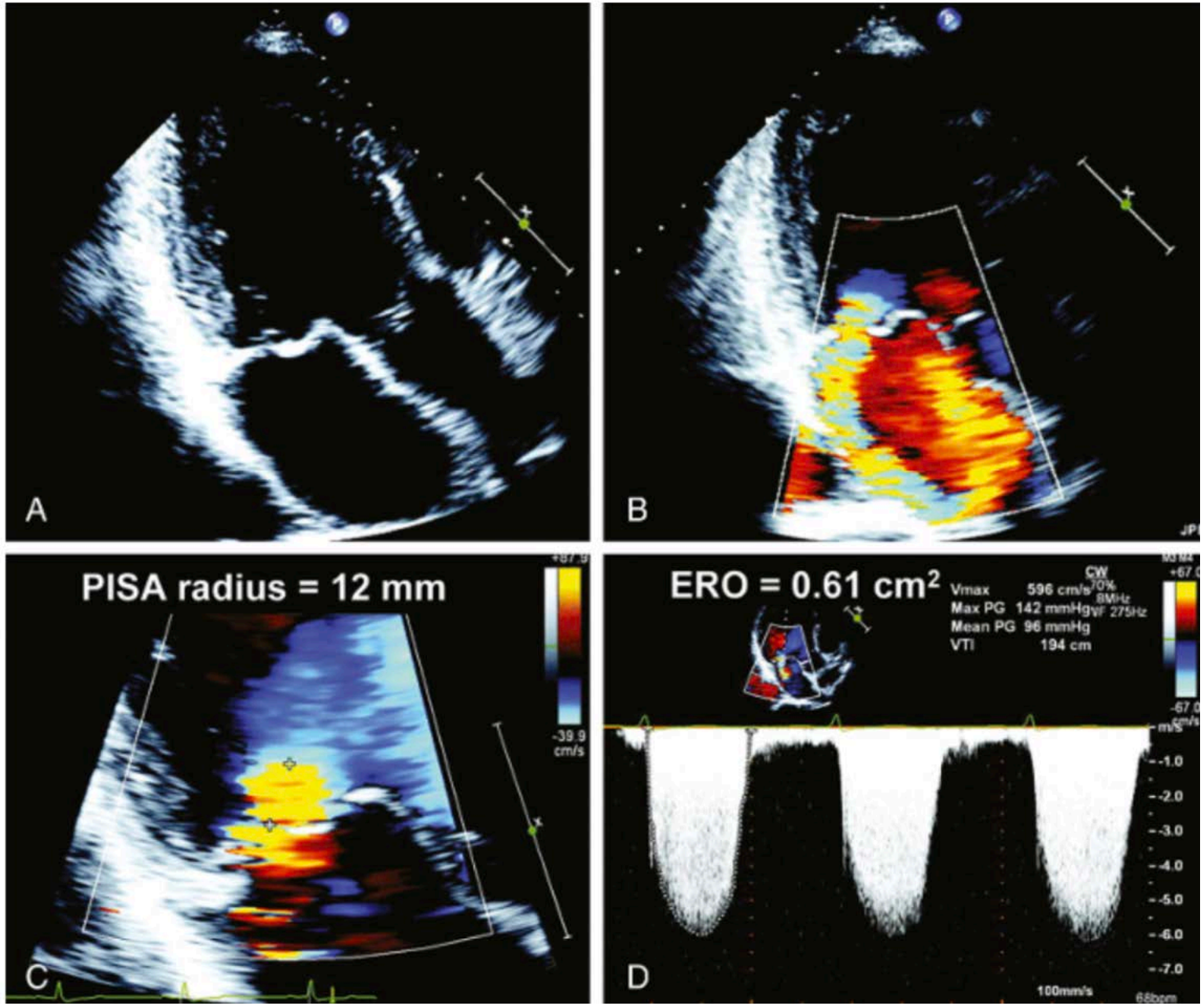

Secondary mitral regurgitation

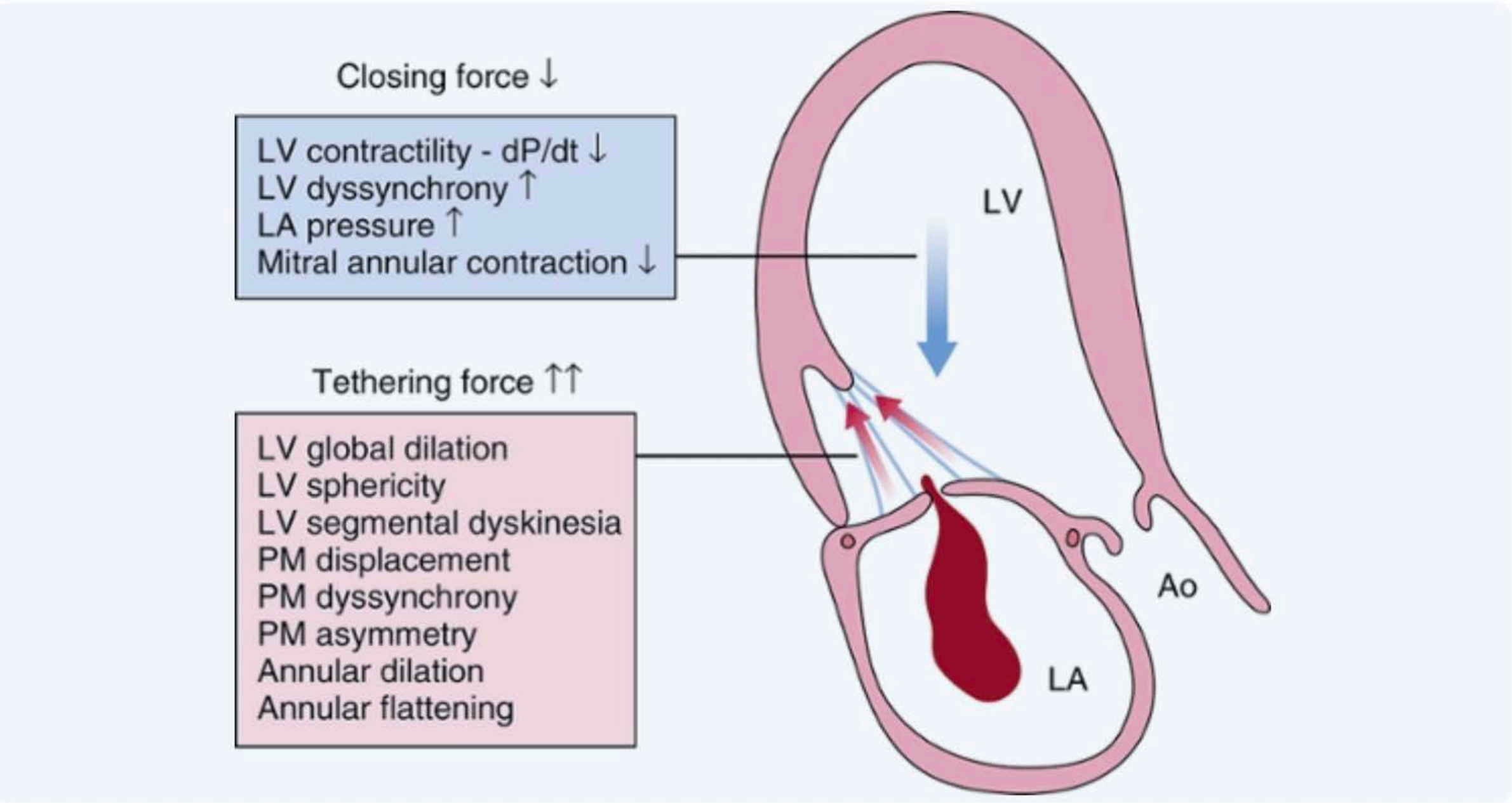

Secondary mitral regurgitation

- **Symptoms**
- Patients with secondary MR related to LV dysfunction often present with HF symptoms, but many are asymptomatic (at least with regard to the MR), with MR detected incidentally on physical examination or echocardiography. AF is common.
- **Physical Examination**
- An apical S_3 is a common finding. Unlike primary MR, the systolic murmur of secondary MR related to LV dilation may be soft and barely audible, particularly in those patients with nonholosystolic MR that becomes minimal in midsystole. Thus, the physical examination can be misleading regarding the presence and severity of secondary MR. The murmur of papillary muscle dysfunction may occur in late systole and is highly variable, often accentuated or holosystolic during acute myocardial ischemia and absent when ischemia is relieved.
- **Echocardiography**
- Quantifying the severity of secondary MR by echocardiography has a number of limitations. Using the standard PISA method to assess MR severity, an EROA of 0.2 cm^2 has been associated with worse prognosis in secondary MR. Thus, European guidelines have used this cutoff to define “severe” disease.

Secondary mitral regurgitation: treatment

- In contrast to primary MR, a beneficial effect of medical therapy in patients with secondary MR, with respect to both valve function and clinical outcomes, is well established.
- Medical therapies have been shown to reduce MR in up to 40% of patients and are associated with improved outcomes.
- Guideline-directed medical therapy (GDMT) including inhibitors of the renin-angiotensin-aldosterone system (RAAS) and beta-adrenergic blockers can significantly reduce secondary MR in 30% to 40% of patients with HF.
- In addition, HF guidelines have been updated to include the use of angiotensin receptor neprilysin inhibition (ARNI) and SGLT2 inhibitors in the treatment of symptomatic LV systolic dysfunction.
- Significant reductions in secondary MR also occur with cardiac resynchronization therapy (CRT).

European Heart Journal (2007) 28, 1358–1365
doi:10.1093/eurheartj/ehm001

EUROPEAN SOCIETY OF CARDIOLOGY®

Clinical research
Valvular heart disease

What are the characteristics of patients with severe, symptomatic, mitral regurgitation who are denied surgery?

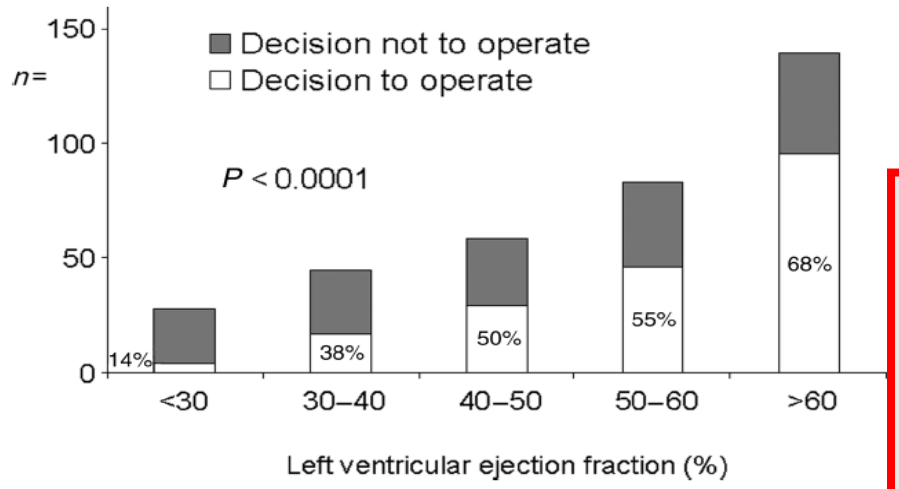

53% pts with EF between 60 and 30%!!!

Table 3 Factors associated with a decision not to operate. Multivariable analysis

	P	Odds ratio	95% CI
LVEF (per 10% decrease)	0.0002	1.39	(1.17–1.66)
Aetiology	0.0006		
Ischaemic		1	
Non-ischaemic		4.44	(1.96–10.76)
Age (per 10-year increase)	0.001	1.40	(1.15–1.72)
Charlson comorbidity index (per 1 point increase)	0.004	1.38	(1.12–1.72)
Degree of MR	0.005		
Grade 4/4		1	
Grade 3/4		2.23	(1.28–3.29)

Hosmer-Lemeshow goodness-of-fit $\chi 2 = 9.84$ (df = 8), $P = 0.28$.

1958: First Cardiac Valve

Ing. Miles "Lowell" Edwards

Dr. Albert Starr

University of Oregon Medical School

Albert Starr in 1960 implanted the first cardiac valve

STARR-EDWARDS

SURGERY

PERCUTANEOUS INTERVENTIONS

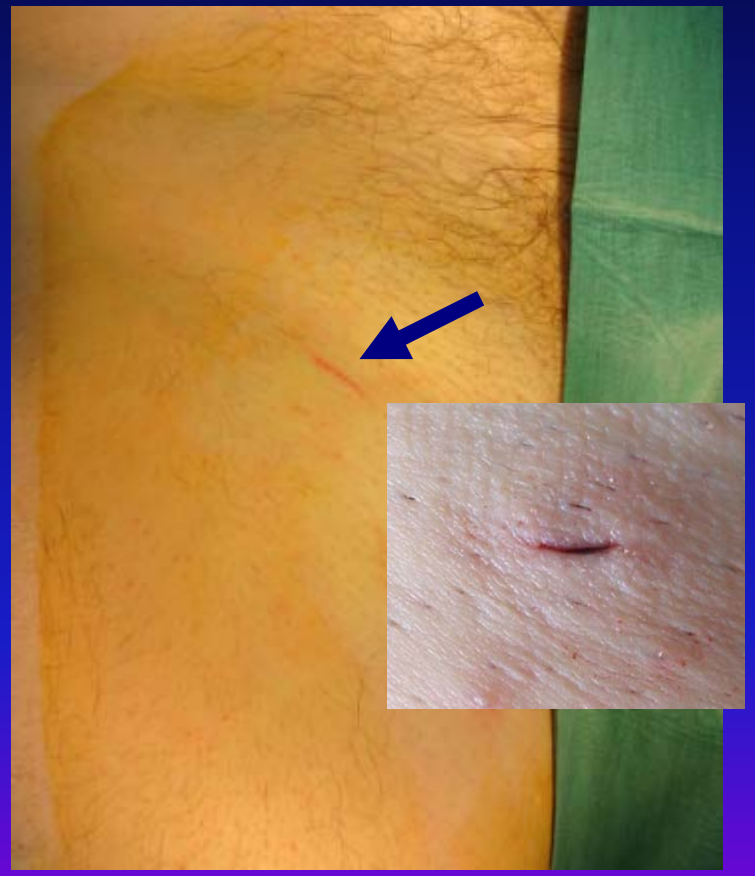

MITRACLIP

Mitraclip Plus Medical Therapy Versus Medical Therapy Alone for Functional Mitral Regurgitation: A Meta-Analysis

Cardiol Ther (2020) 9:5–17

Sunny Goel · Ravi Teja Pasam · Karan Wats · Srilekha Chava · Joseph Gotesman · Abhishek Sharma · Bilal Ahmad Malik · Sergey Avzenberg · Robert Frankel · Jacob Shani · Umesh Gidwani

A - Overall Mortality

Study or Subgroup	MitraClip Events	MitraClip Total	Medical Therapy Events	Medical Therapy Total	Weight	Odds Ratio M-H, Random, 95% CI	Year
Asgar et al.	9	50	10	42	12.3%	0.70 [0.26, 1.93]	2016
Armeni et al.	20	232	27	151	23.3%	0.43 [0.23, 0.80]	2016
Stone et al.	80	302	121	312	37.2%	0.57 [0.40, 0.80]	2018
Obadia et al.	37	152	34	152	27.2%	1.12 [0.66, 1.90]	2018
Total (95% CI)		736		657	100.0%	0.66 [0.44, 0.99]	
Total events	146		192				

Heterogeneity: Tau² = 0.09; Chi² = 6.22, df = 3 (P = 0.10); I² = 52%
Test for overall effect: Z = 2.01 (P = 0.04)

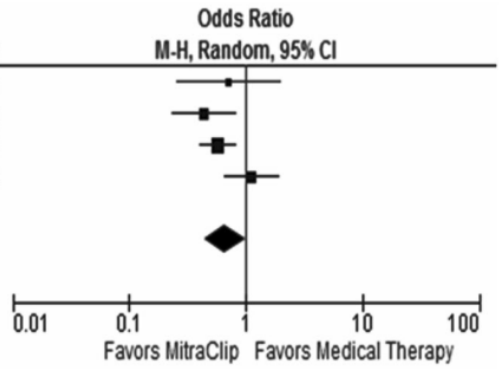

B - HF Re-hospitalization

Study or Subgroup	log[Odds Ratio]	SE	Weight	Odds Ratio IV, Random, 95% CI	Year
Giannini et al.	-0.29	0.055	32.7%	0.75 [0.67, 0.83]	2016
Asgar et al.	-1.966	0.497	13.5%	0.14 [0.05, 0.37]	2016
Stone et al.	-0.755	0.17	28.4%	0.47 [0.34, 0.66]	2018
Obadia et al.	0.049	0.231	25.3%	1.05 [0.67, 1.65]	2018
Total (95% CI)			100.0%	0.57 [0.36, 0.91]	

Heterogeneity: Tau² = 0.17; Chi² = 20.30, df = 3 (P = 0.0001); I² = 85%
Test for overall effect: Z = 2.37 (P = 0.02)

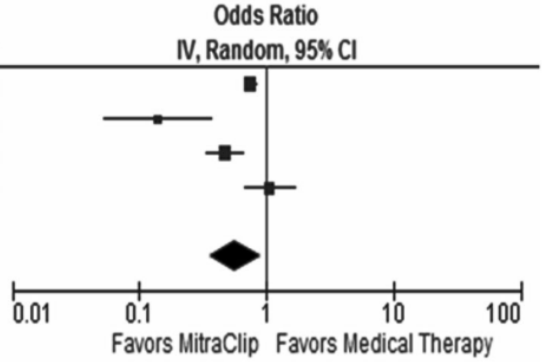

The evolution of the MitraClipTM therapy with the historical designs

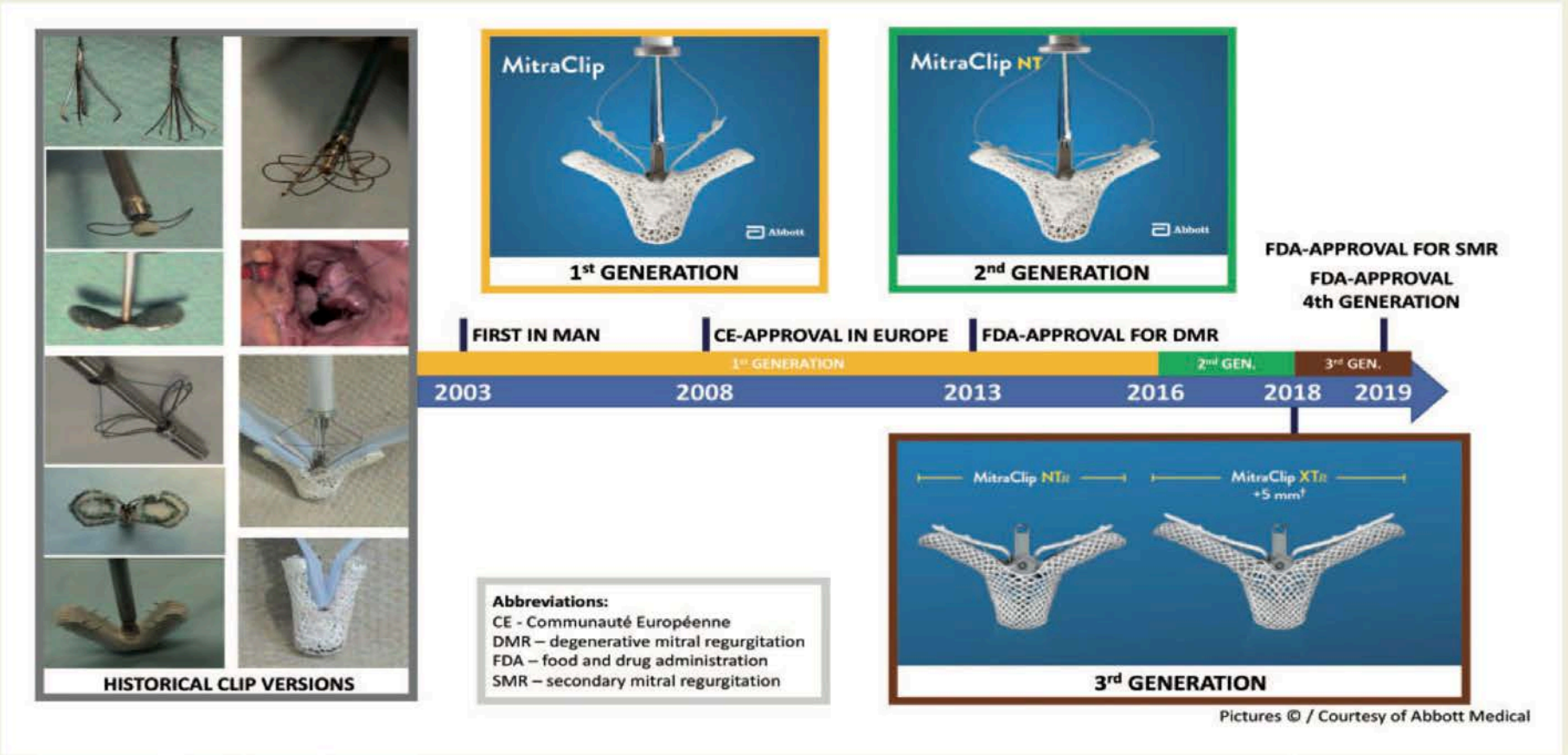

VALVULAR HEART DISEASE GUIDELINES:

ORGANIC OR PRIMARY MITRAL REGURGITATION

UMG

ESC
European Society of Cardiology

VHD Guidelines 2021

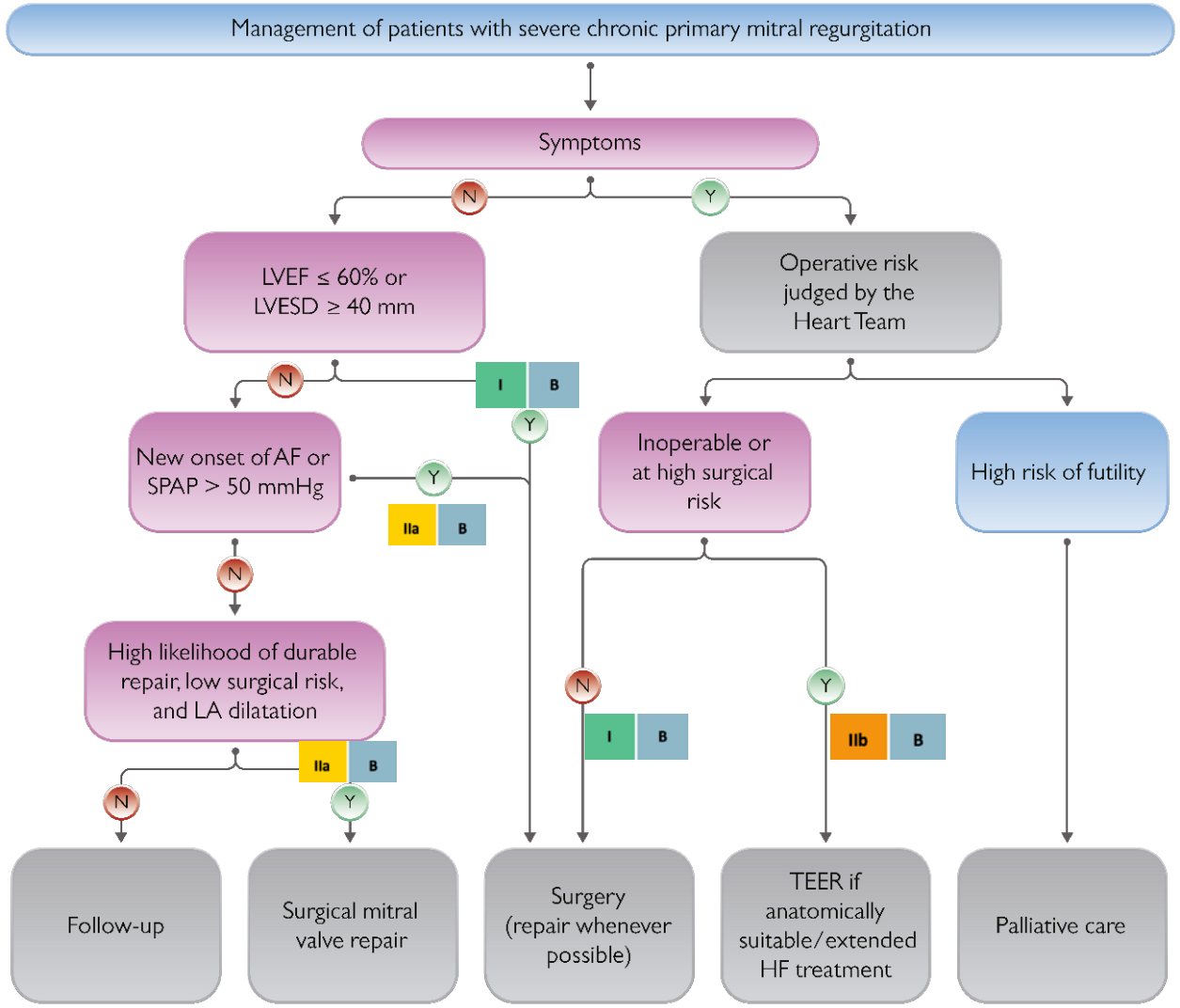

When to Operate in Mitral Regurgitation
Changing Management Trends

- 1970's: Delay surgery until symptoms uncontrollable with meds
- 1980's: Surgery when resting LVEF drops or LV systolic volume enlarges
- 1990's: Surgery with onset of symptoms or when occult LV dysfunction identified (by exercise echo or Doppler dp/dt)
- 2017-2021 : operate when MR becomes severe, despite symptoms or LV function
- 2017-2021 : in high surgical risk patients TEER

Comparison of Event-free Survival after early Surgery vs Conventional Management in Initially Asymptomatic Pts with Severe MR

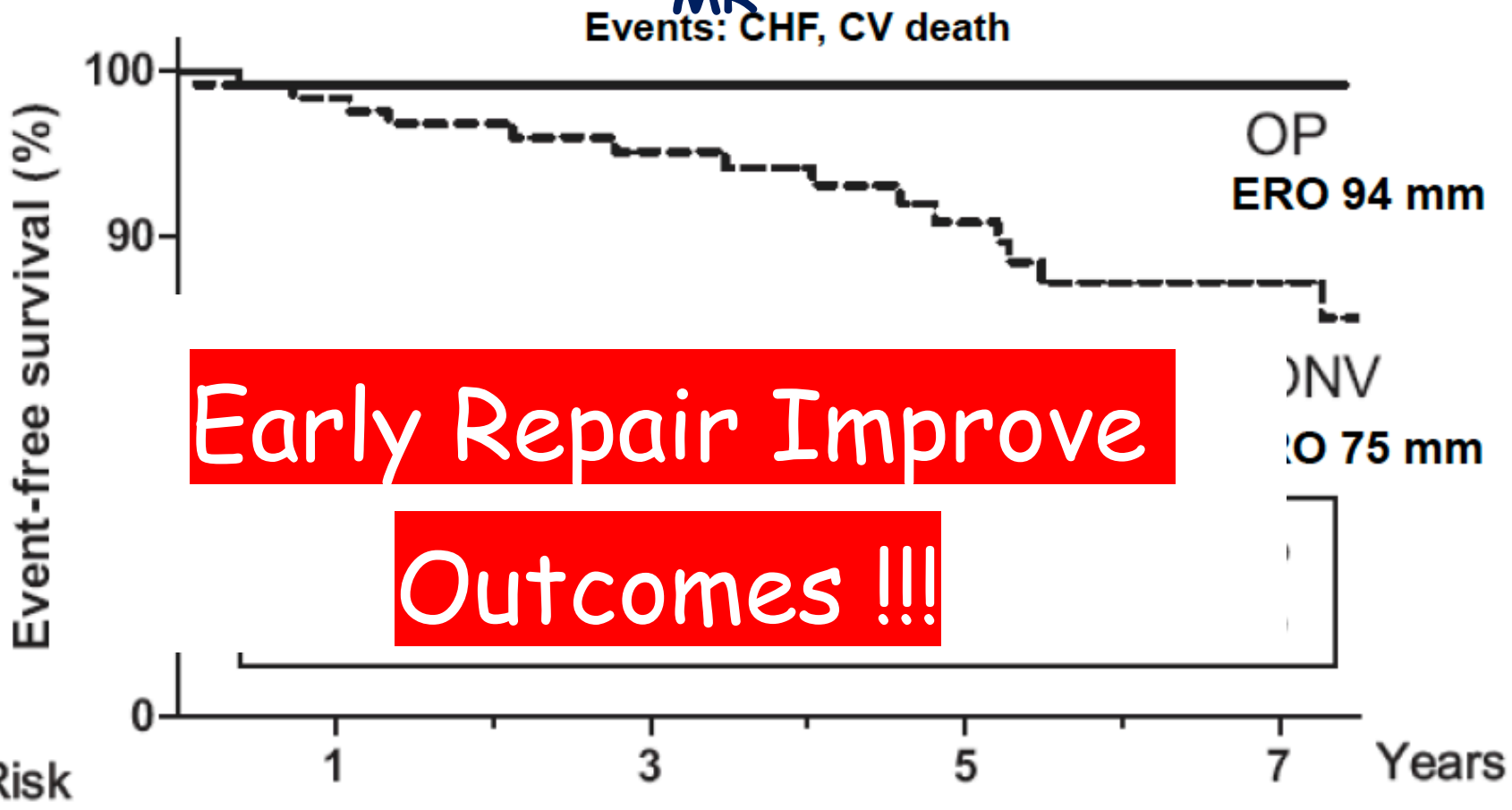

Early Repair Improve Outcomes !!!

No at Risk					
OP	127	125	106	72	43
CONV	127	125	105	78	44

Circulation 2009;119:797-804

ESC
European Society of Cardiology

VHD Guidelines 2021

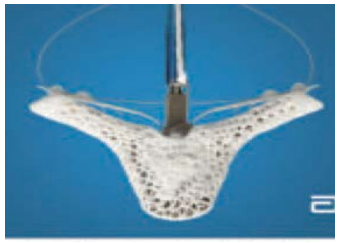

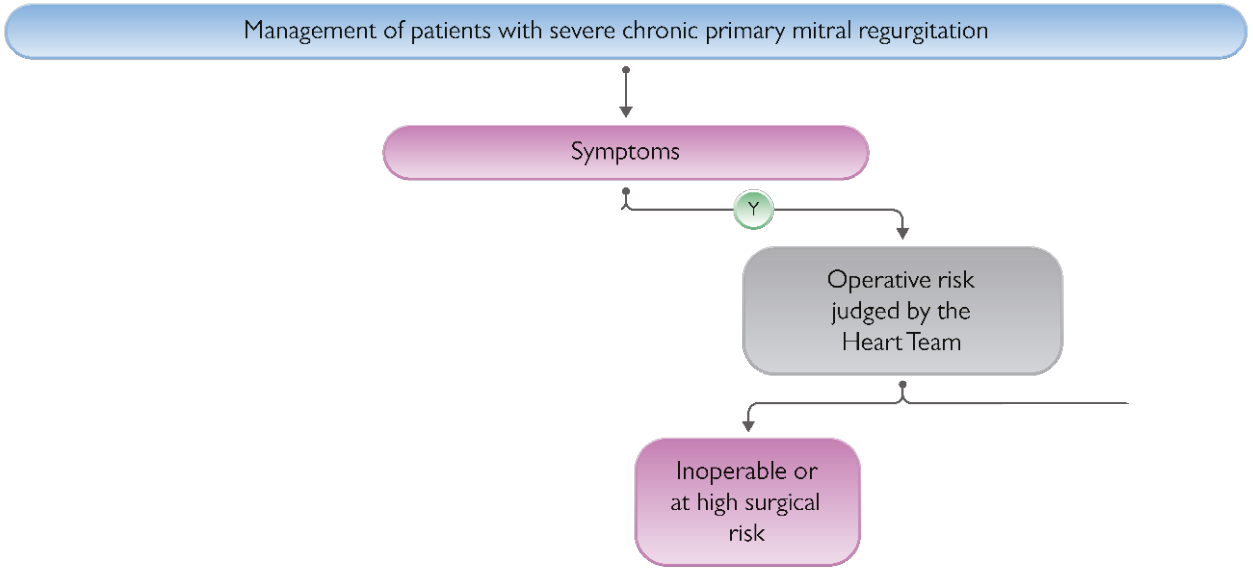

Transcatheter mitral valve implantation for severe PMR is a safe alternative in patients with contraindications for surgery or high operative risk.[299–302] TEER is the most evidenced, while the safety and efficacy of other techniques have been demonstrated in smaller series.[303–306] The efficacy of more recent TEER system iterations[307] will be investigated in high-risk (MITRA-HR study NCT03271762)[308] and intermediate-risk patients (REPAIR-MR study NCT04198870).

Y

IIb B

TEER may be considered in symptomatic patients who fulfil the echocardiographic criteria of eligibility, are judged inoperable or at high surgical risk by the Heart Team and for whom the procedure is not considered futile.	IIb	B	TEER if anatomically suitable/extended HF treatment

S.B. male, 85 yrs (78 yrs in 2014)

- Cirrhosis
- Dyslipidemia
- Hypertension
- Chronic atrial fibrillation in TAO
- Reduced myocardial function (EF 50%)
- Degenerative mitral regurgitation 4+, with LPM flail
- NYHA class III-IV

S.B. male, 78 yrs

Basal Echo (TEE):
Sept 8th, 2014

Basal Echo (TEE):
Sept 8th, 2014

S.B. male, 78 yrs

S.B. male, 78 yrs

Basal Echo (TEE):
Sept 8th, 2014

S.B. male, 78 yrs

Intraprocedural Echo:
Sept 8th, 2014

S.B. male, 78 yrs

Intraprocedural Echo:
Sept 8th, 2014

Follow Up

- The patient was asymptomatic after the procedure: (NYHA I-II)
- In December 2020 he referred worsening dyspnoea (with unchanged echocardiographic parameters), due to acute renal failure secondary to a prostatic cancer.
- The patient underwent prostatectomy in January 2021.
- He underwent echocardiography in September 2021: clinically stable and improved dyspnoea (NYHA I-II)

S.B. male, 78 yrs

Sept 8th, 2021

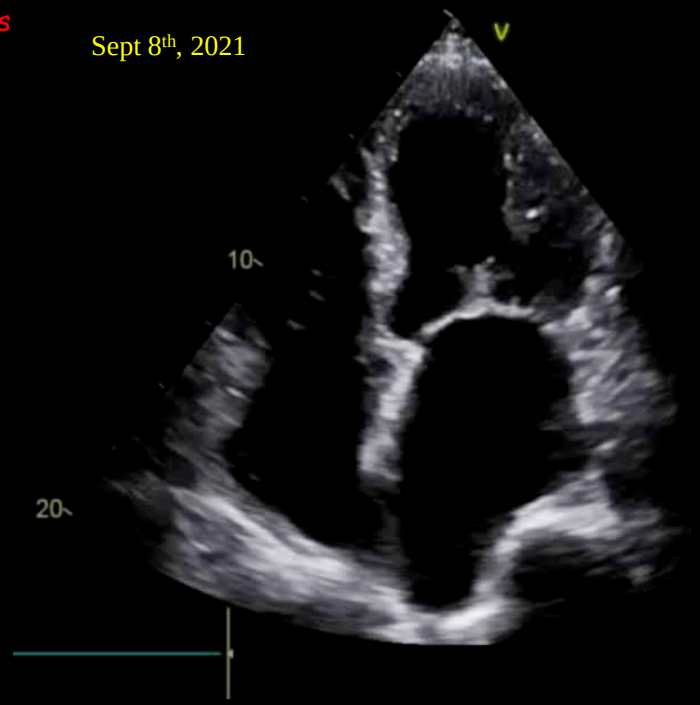

S.B. male, 78 yrs

Sept 8th, 2021

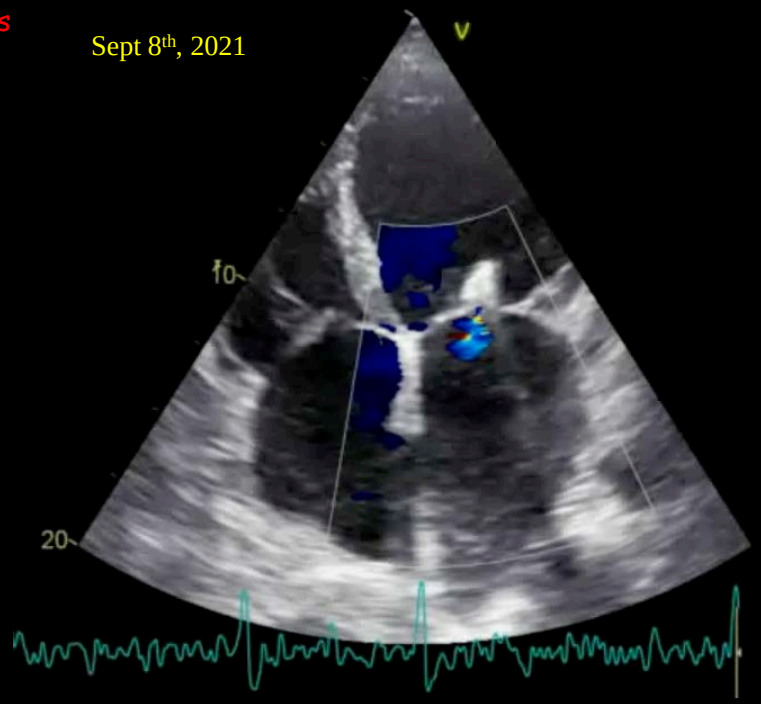

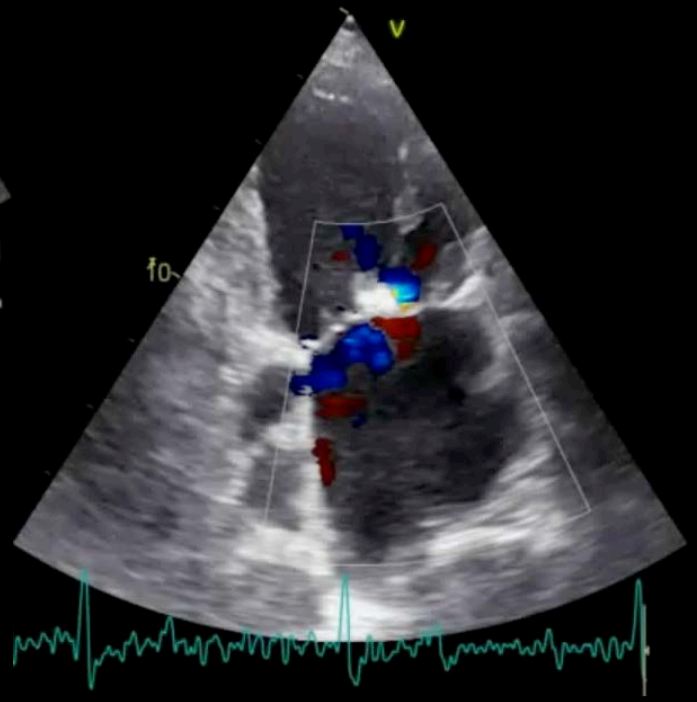

VALVULAR HEART DISEASE GUIDELINES:

FUNCTIONAL OR SECONDARY MITRAL REGURGITATION

VHD Guidelines 2021

ESC
European Society of Cardiology

Indications for mitral valve intervention in chronic severe secondary mitral regurgitation			
2017 VHD Guidelines	**Class**	**2021 VHD Guidelines**	**Class**
		Valve surgery/intervention is recommended only in patients with severe SMR who remain symptomatic despite GDMT (including CRT if indicated) and has to be decided by a structured collaborative Heart Team.	I

What is new (15)

Indications for mitral valve intervention in chronic severe secondary mitral regurgitation			
2017 VHD Guidelines	**Class**	**2021 VHD Guidelines**	**Class**
Patients with concomitant coronary artery or other cardiac disease requiring treatment			
Surgery is indicated in patients with severe SMR undergoing CABG and LVEF >30%.	I	Valve surgery is recommended in patients undergoing CABG or other cardiac surgery.	I

2021 ESC/EACTS Guidelines for the management of valvular heart disease
(European Heart Journal; 2021 – doi: 10.1093/eurheartj/ehab395; European Journal of Cardio-Thoracic Surgery; 2021 – doi: 10.1093/ejcts/ezab389)

Chronic Severe Secondary Mitral Regurgitation

What is new?

2017 VHD Guidelines	Class	2021 VHD Guidelines	Class
Patients with concomitant coronary artery or other cardiac disease requiring treatment			
		In symptomatic patients, who are judged not appropriate for surgery by the Heart Team on the basis of their individual characteristics, PCI (and/or TAVI) possibly followed by TEER (in case of persisting severe SMR) should be considered.	**IIa**

2021 ESC/EACTS Guidelines for the management of valvular heart disease

Chronic Severe Secondary Mitral Regurgitation

What is new?

2017 VHD Guidelines	Class	2021 VHD Guidelines	Class
Patients without concomitant coronary artery or other cardiac disease requiring treatment			
When revascularization is not indicated and surgical risk is not low, a percutaneous edge-to-edge procedure may be considered in patients with severe secondary mitral regurgitation and LVEF >30% who remain symptomatic despite optimal medical management (including CRT if indicated) and who have a suitable valve morphology by echocardiography, avoiding futility.	**IIb**	TEER should be considered in selected symptomatic patients, not eligible for surgery and fulfilling criteria suggesting an increased chance of responding to the therapy.	**IIa**

2021 ESC/EACTS Guidelines for the management of valvular heart disease

The NEW ENGLAND JOURNAL of MEDICINE

ORIGINAL ARTICLE

Percutaneous Repair or Medical Treatment for Secondary Mitral Regurgitation

J.-F. Obadia, D. Messika-Zeitoun, G. Leurent, B. Iung, G. Bonnet, N. Piriou, T. Lefèvre, C. Piot, F. Rouleau, D. Carrié, M. Nejjari, P. Ohlmann, F. Leclercq, C. Saint Etienne, E. Teiger, L. Leroux, N. Karam, N. Michel, M. Gilard, E. Donal, J.-N. Trochu, B. Cormier, X. Armoiry, F. Boutitie, D. Maucort-Boulch, C. Barnel, G. Samson, P. Guerin, A. Vahanian, and N. Mewton, for the MITRA-FR Investigators*

Mitra-FR
Death and Rehospitalization for HF

Primary composite endpoint *(99% follow-up)*

- All-Cause Death
- Unplanned rehospitalization for HF

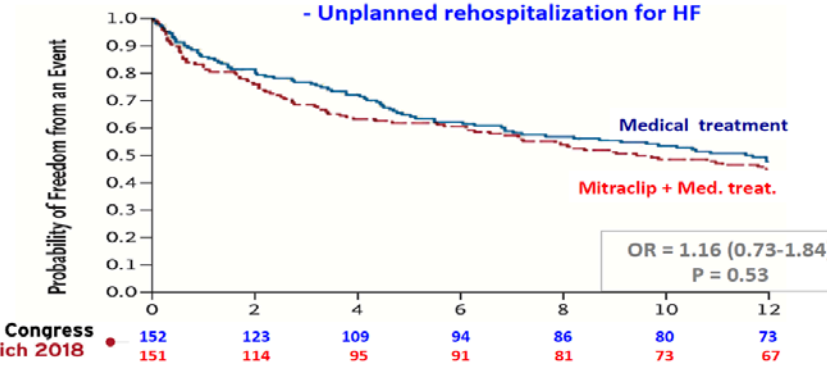

ESC Congress
Munich 2018

JF Obadia et al. NEJM August 27, 2018; DOI: 10.1056/NEJMoa1805.

The NEW ENGLAND JOURNAL of MEDICINE

ORIGINAL ARTICLE

Transcatheter Mitral-Valve Repair in Patients with Heart Failure

G.W. Stone, J.A. Lindenfeld, W.T. Abraham, S. Kar, D.S. Lim, J.M. Mishell, B. Whisenant, P.A. Grayburn, M. Rinaldi, S.R. Kapadia, V. Rajagopal, I.J. Sarembock, A. Brieke, S.O. Marx, D.J. Cohen, N.J. Weissman, and M.J. Mack, for the COAPT Investigators*

COAPT

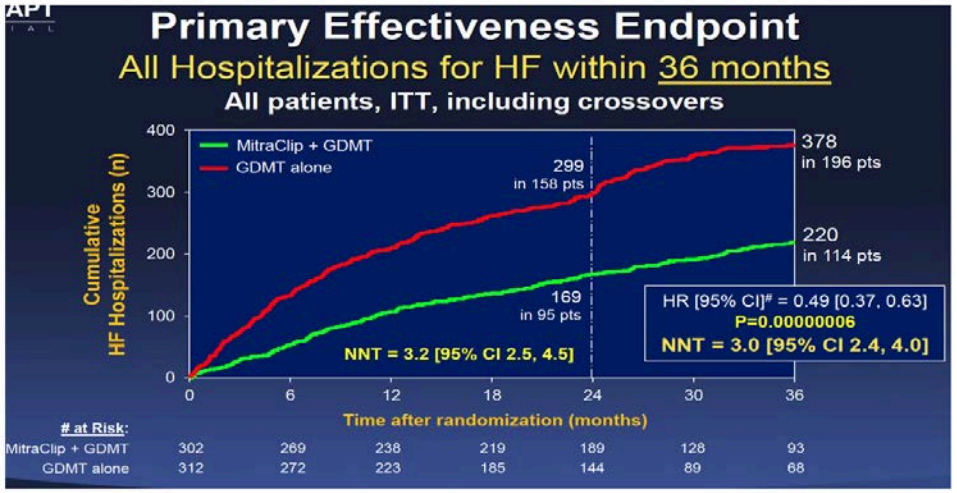

JW Stone. Published on line Semptember 2018 NEJM

Why COAPT e MITRA-FR are so different?

Possible Reasons

	MITRA-FR (n=304)	COAPT (n=614)
Study Design		
LVESD, mm	--	≤ 70
LV ejection fraction %	≥ 15 and ≤ 40	≥ 20 and ≤ 50
Severe MR entry criteria	Severe FMR by EU guidelines: EROA >20 mm^2 or RV >30 mL/beat	Severe FMR by US guidelines: EROA >30 mm^2 or RV >45 mL/beat
MR severity, %		
EROA 20-29 mm^2	52	14
EROA 30-39 mm^2	32	46
EROA ≥ 40 mm^2	16	41
EROA (mean ± SD)	31 ± 10 mm^2	41 ± 15 mm^2
LVEDV (mean ± SD)	135 ± 35 mL/m^2	101 ± 34 mL/m^2

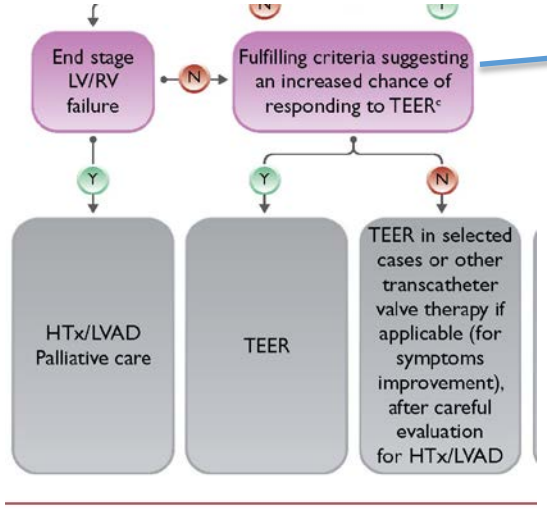

COAPT criteria

Inclusion criteria:

- Severe SMR
- Symptomatic heart failure (NYHA class II, III or ambulatory IV) despite optimized GDMT
- LVEF 20–50%
- LV end-systolic diameter ≤70 mm
- At least one heart failure hospitalization within the previous year or increased natriuretic peptide levels
- Anatomy judged suitable for TEER

Exclusion criteria:

- Severe disability/frailty
- Hypertrophic cardiomyopathy, restrictive cardiomyopathy, constrictive pericarditis, or any other structural heart disease causing heart failure other than dilated cardiomyopathy of either ischemic or non-ischaemic etiology
- Infiltrative cardiomyopathies (e.g. amyloidosis, haemochromatosis, sarcoidosis)
- Estimated SPAP >70 mmHg assessed by echocardiography or right heart catheterization
- Haemodynamic instability defined as systolic pressure <90 mmHg with or without afterload reduction, cardiogenic shock or the need for inotropic support or intra-aortic balloon pump or other haemodynamic support device
- Physical evidence of right-sided congestive heart failure with echocardiographic evidence of moderate or severe RV dysfunction
- Mitral valve orifice area <4.0 cm^2 by site-assessed TTE
- Coronary, aortic or tricuspid valve disease requiring surgery

ESC
European Society of Cardiology

2021 ESC/EACTS Guidelines for the management of valvular heart disease

Chronic Severe Secondary Mitral Regurgitation

What is new?

2017 VHD Guidelines	Class	2021 VHD Guidelines	Class
Patients without concomitant coronary artery or other cardiac disease requiring treatment			
In patients with severe SMR and LVEF <30% who remain symptomatic despite optimal medical management (including CRT if indicated) and who have no option for revascularization, the Heart Team may consider a percutaneous edge-to-edge procedure or valve surgery after careful evaluation for a ventricular assist device or heart transplant according to individual patient characteristics.	**IIb**	In high-risk symptomatic patients not eligible for surgery and not fulfilling the criteria suggesting an increased chance of responding to TEER, the Heart Team may consider in selected cases a TEER procedure or other trans-catheter valve therapy if applicable, after careful evaluation for ventricular assist device or heart transplant.	**IIb**

2021 ESC/EACTS Guidelines for the management of valvular heart disease

1

TEER may be considered only in selected cases when the COAPT criteria are not fulfilled with the aim of improving symptoms and quality of life.

2

In patients with less severe SMR (EROA <30 mm^2) and advanced LV dilatation/dysfunction, the prognostic benefit of MitraClip remains unproven

PM, male 80 years old in 2018

Hypertension
Permanent AF, treated with NOAC

2018
NYHA IV pulmonary edema + sincope
Echo: - EF 25-30%
- severe LFLG aortic stenosis (Area 0,8 cm, Vmax 3,2 m/sec, medium Gr 30 mmHg)
-mild-moderate aortic regurgitation (PHT 521 msec)
-severe FMR (EROA 0,5 cm^2)
Echo-dobutamin: no contractile reserve.
Normal coronary artery

HEART Team judges patient to proibitive surgical risk

PM, male, 80 years old
2018 October: TAVI with Evolut R 29 mm

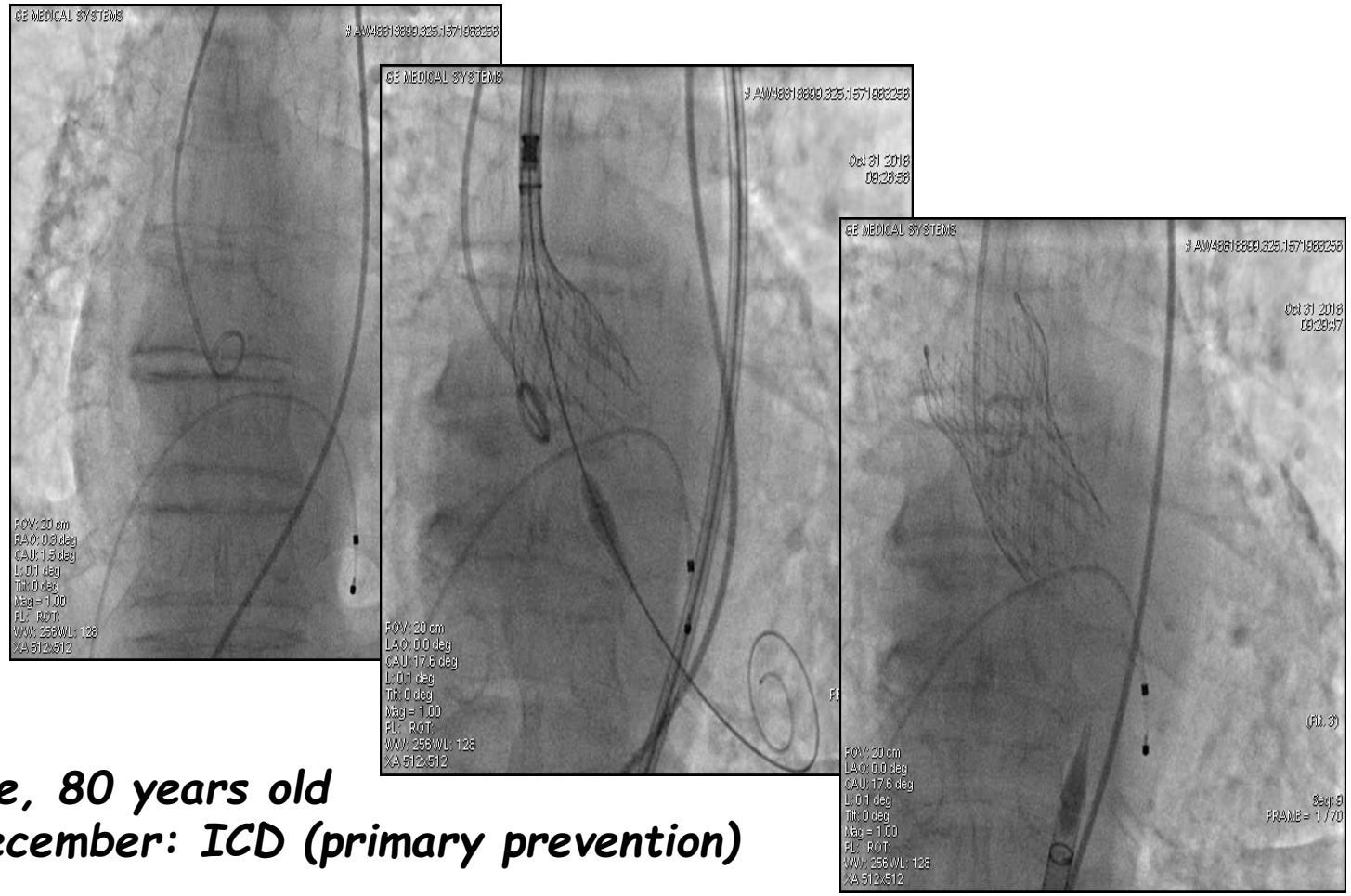

PM, male, 80 years old
2018 December: ICD (primary prevention)

PM, 80 years old

Oct-Dec, 2018
NYHA IV
EF 30% TAVI + ICD

March, 2019
NYHA III

Echo:
- EF 33%
- Normal aortic prosthesis index (Vmax 1 m/s; Medium Gr 5.32 mmHg)
- Severe FMR (v.c. 7 cm; EROA 0.4 cm^2)

PM, 80 yrs
March 2019

PM, 82 anni
September 2021
NYHA II
Echo:
- FE 35%
- Normal aortic prosthesis index (Vmax 1,54 m/s; Medium Gr 6,4 mmHg)
- Mild residual MR

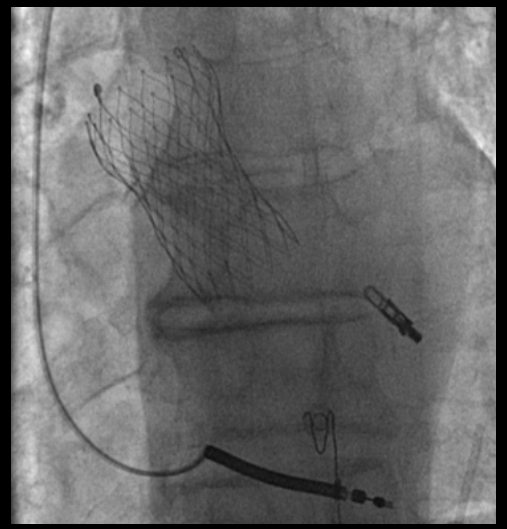

Relationship Between EROA and LVEDV Illustrating Domains That Define Disproportionately Severe, Proportionately Severe, and Nonsevere Functional Mitral Regurgitation

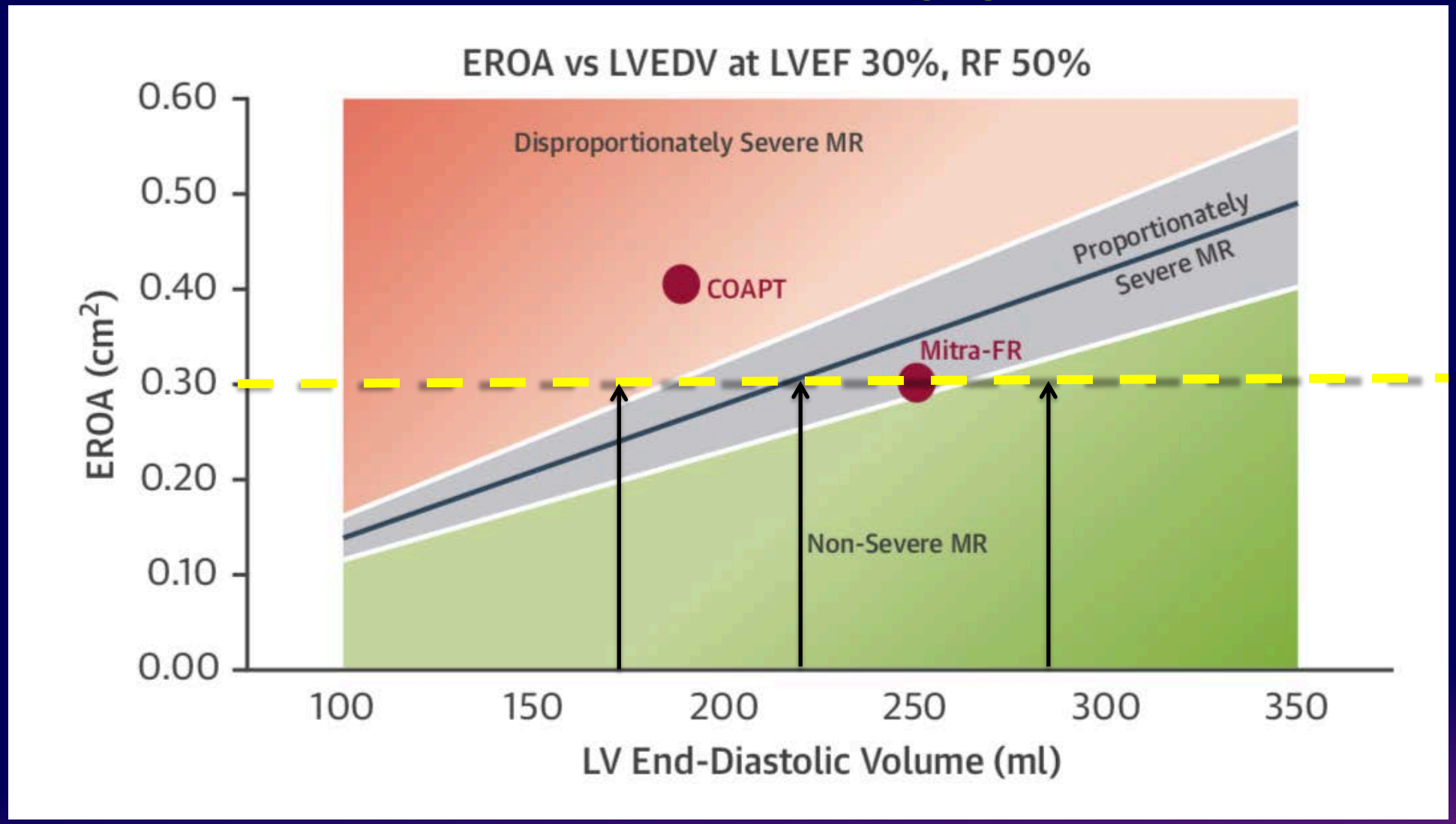

JACC Cardiovasc Imaging. 2019 Feb;12(2):353-362.

Differences in Efficacy of 3 Valve-Directed Procedural Treatments for MR in pts With Proportionate and Disproportionate MR

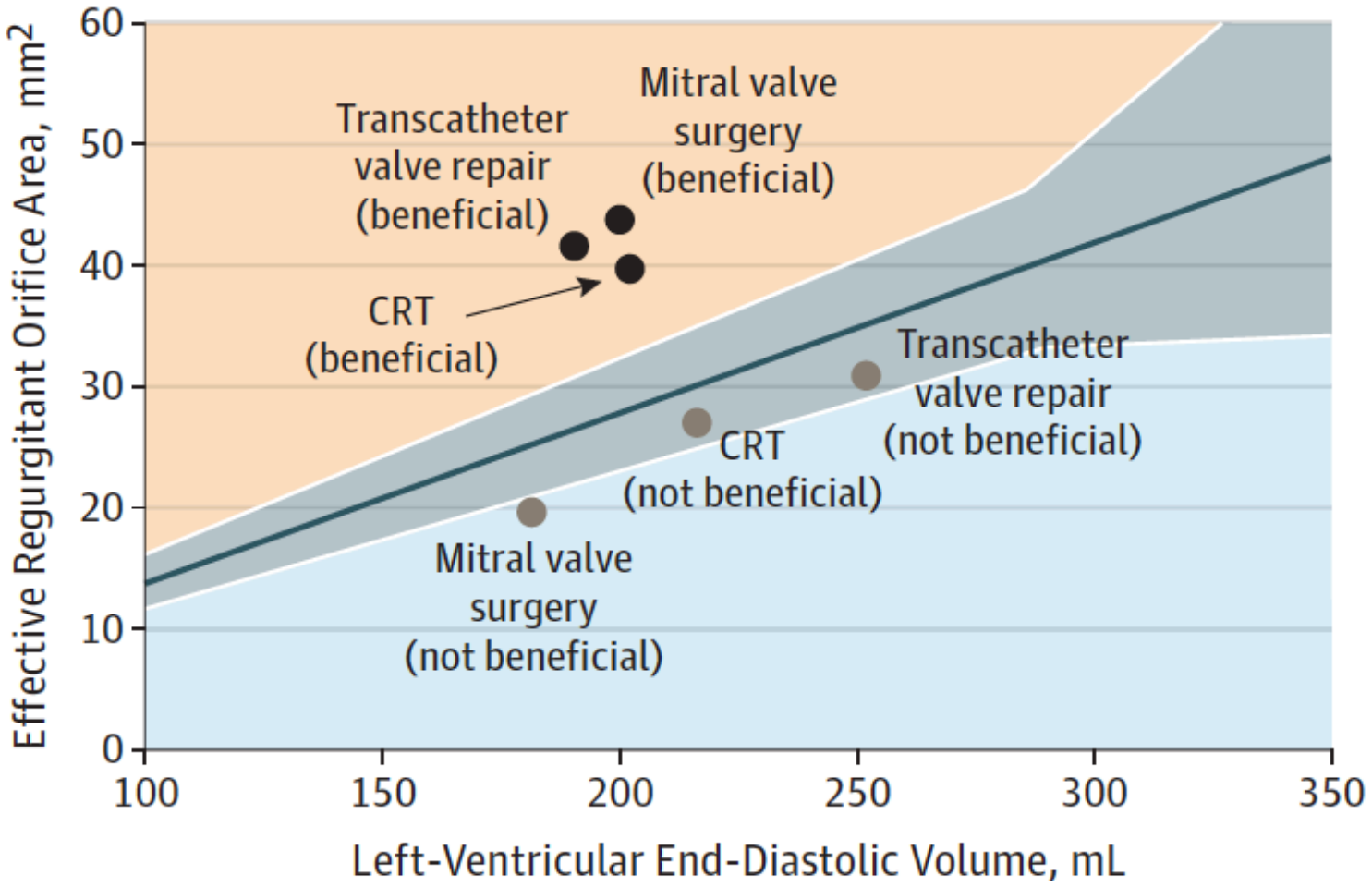

JAMA Cardiol. 2020;5(4):469-475.

PAZIENTE IDEALE PER LA CLIP

EF= 20-50%

IM moderata-severa

Classe II-IV

Pro-BNP $\geq$ 1500

Non candidato a chirurgia.

Volume ventricolare sinistro LVEDV <100 mL/m2 (diametro TS < 70 mm)

Insufficienza mitralica disproporzianata (EROA/LVEDV>0.14).

PAPS < 70 mmHg.

Assenza disfunzione ventricolare destra (Moderata o severa).

Come si impianta una clip metallica

1. La paziente viene monitorizzata, sedata, sottoposta a IOT e curarizzata
2. Si incannula un’arteria radiale per monitoraggio invasivo della PA
3. Si cannula la vena femorale destra
4. Intanto gli ecografisti procedono al posizionamento della sonda dell’ecocardiogramma transesofageo ed effettuano tutte le proiezioni per studiare la mitrale

LVOT

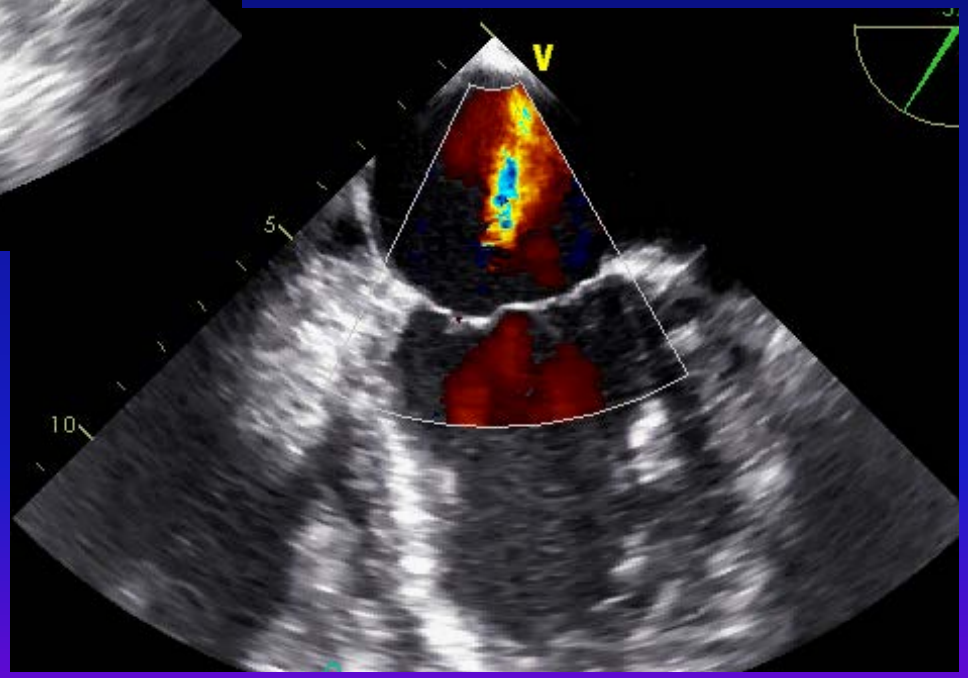

2 Camere Intercommissurale

Come si impianta una clip metallica

5. Dalla vena femorale, si raggiunge l'atrio destro con il Mullins, che viene armato con l'ago di BROCKENBROUGH

6. Si effettua il tenting nella regione superiore e posteriore della fossa ovale

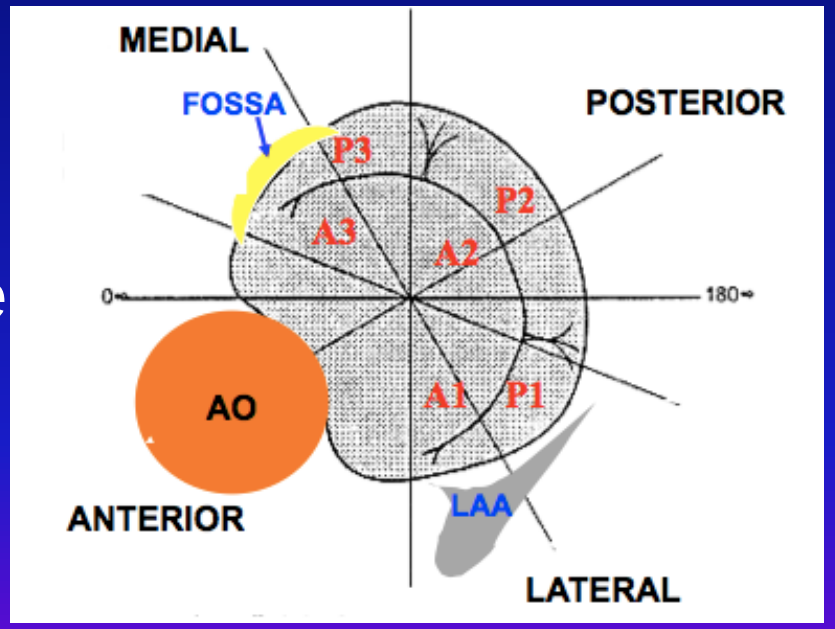

Come si impianta una clip metallica

7. Si cerca la fossa ovale nella proiezione bicavale

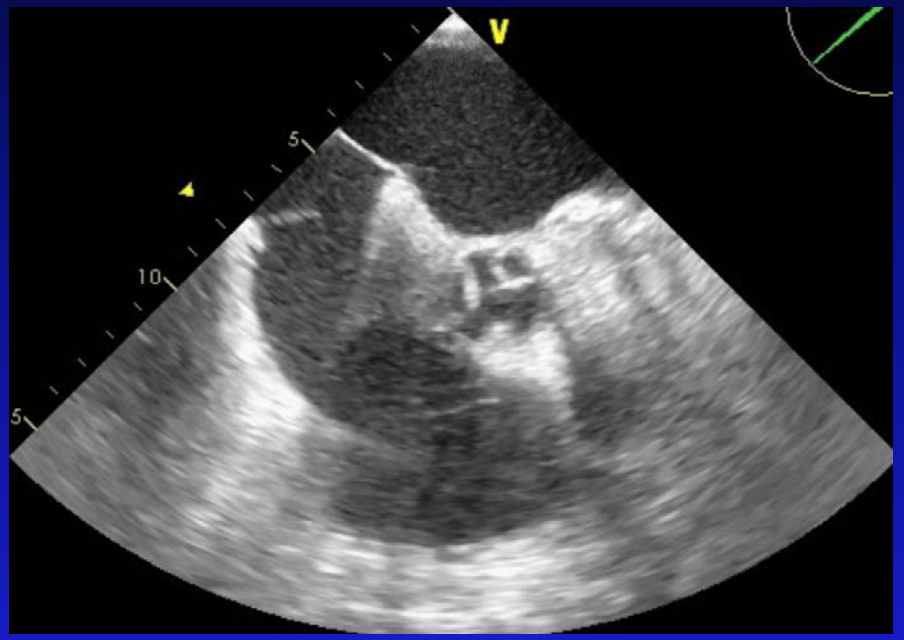

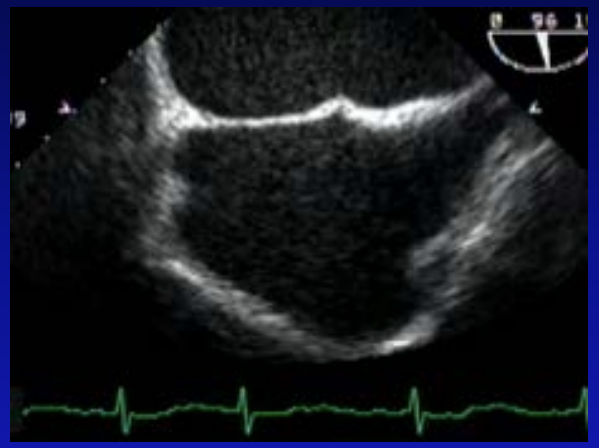

8. Si osserva il tenting anche nella proiezione asse corto alla base per valutare la posizione (Anteriore-Posteriore)

Come si impianta una clip metallica

9. Si osserva il tenting anche nella proiezione 4 o 5 camere per misurare l'altezza dal piano valvolare che deve essere compresa tra 3.5 e 4 cm.

10. Quindi si effettua la puntura transettale, si avanza il Mullins in atrio sx

11. Si somministra UFH (ACT target 250) e si introduce una guida Extra Stiff in a. polmonare sup sx o in atrio

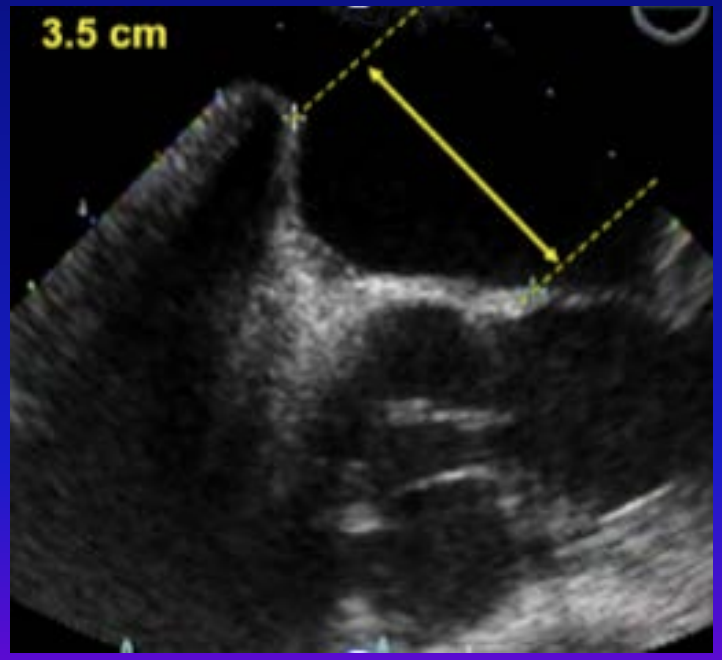

Come si impianta una clip metallica

12. Si effettua pre-dilatazione nel sito di puntura con dilatatori 12-16 F e si posiziona in atrio sx il catetere guida sulla guida lasciata in arteria polmonare



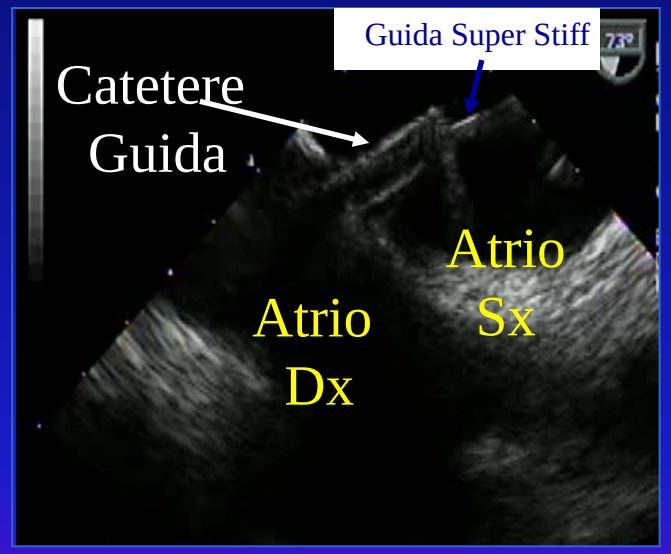

Come si impianta una clip metallica

13. Attraverso il catetere guida posizionato in atrio sinistro si avanza la clip

Passaggio della clip in atrio sx dove si piega per posizionarla perpendicolarmente al piano valvolare

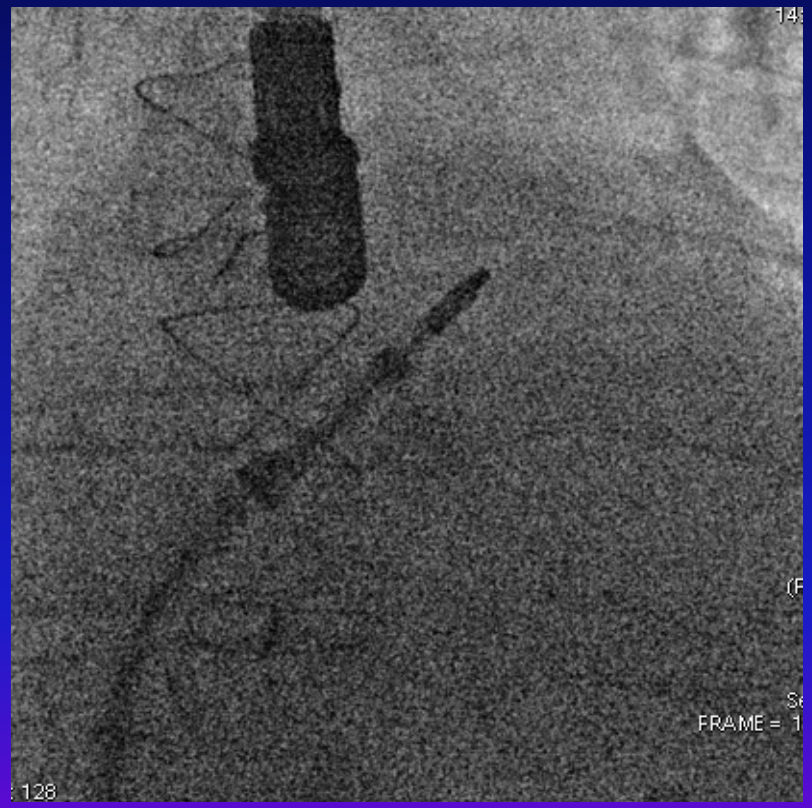

Come si impianta una clip metallica

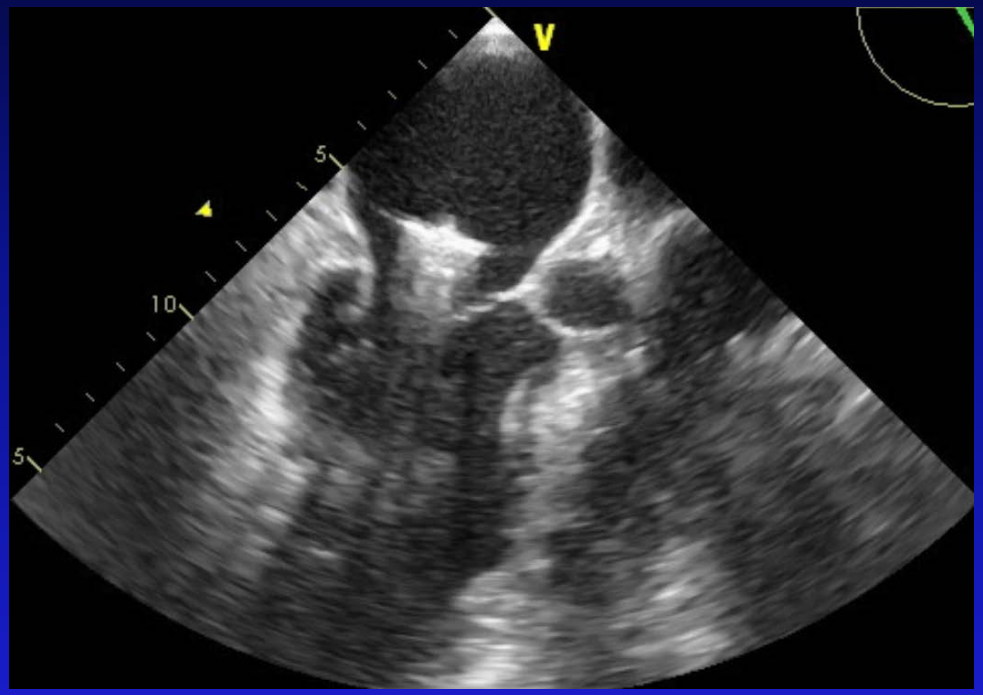

14. Controllo della posizione della clip in LVOT e intercommissurale

Come si impianta una clip metallica

15. Quando la clip e’ sul jet di rigurgito, si scende in ventricolo con i bracci aperti e si tenta il “Grasping”

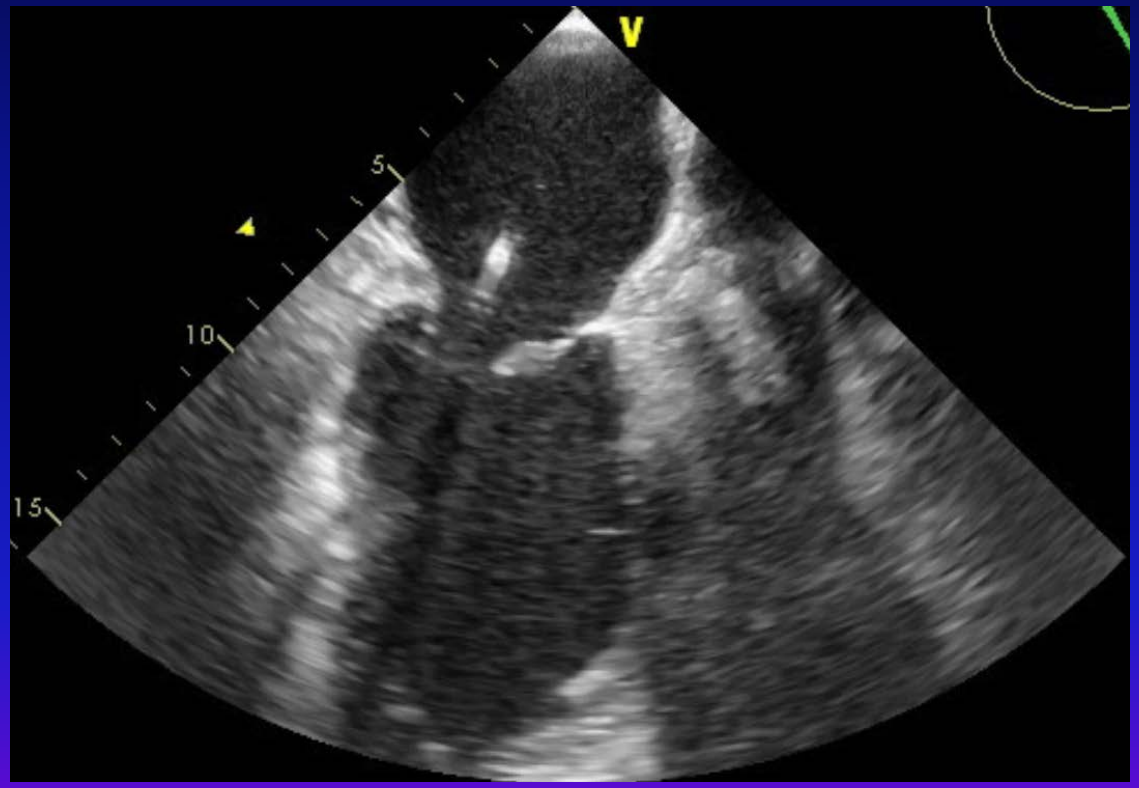

Come si impianta una clip metallica

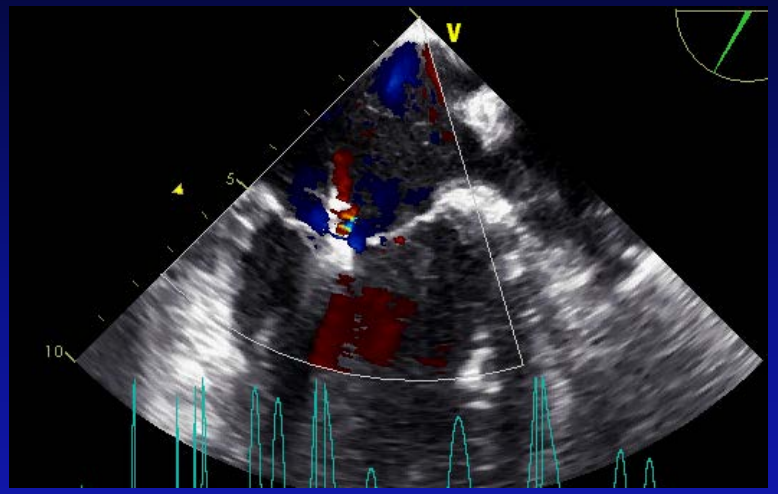

16. Se sono stati catturati sia il LAM che LPM, si chiude la clip completamente e si controlla l'entità dell'eventuale insufficienza residua….

17. Se tutto ok, si rilasciano i due sistemi di sicurezza e la clip non sarà più ricatturabile

Insufficienza mitralica residua 1+

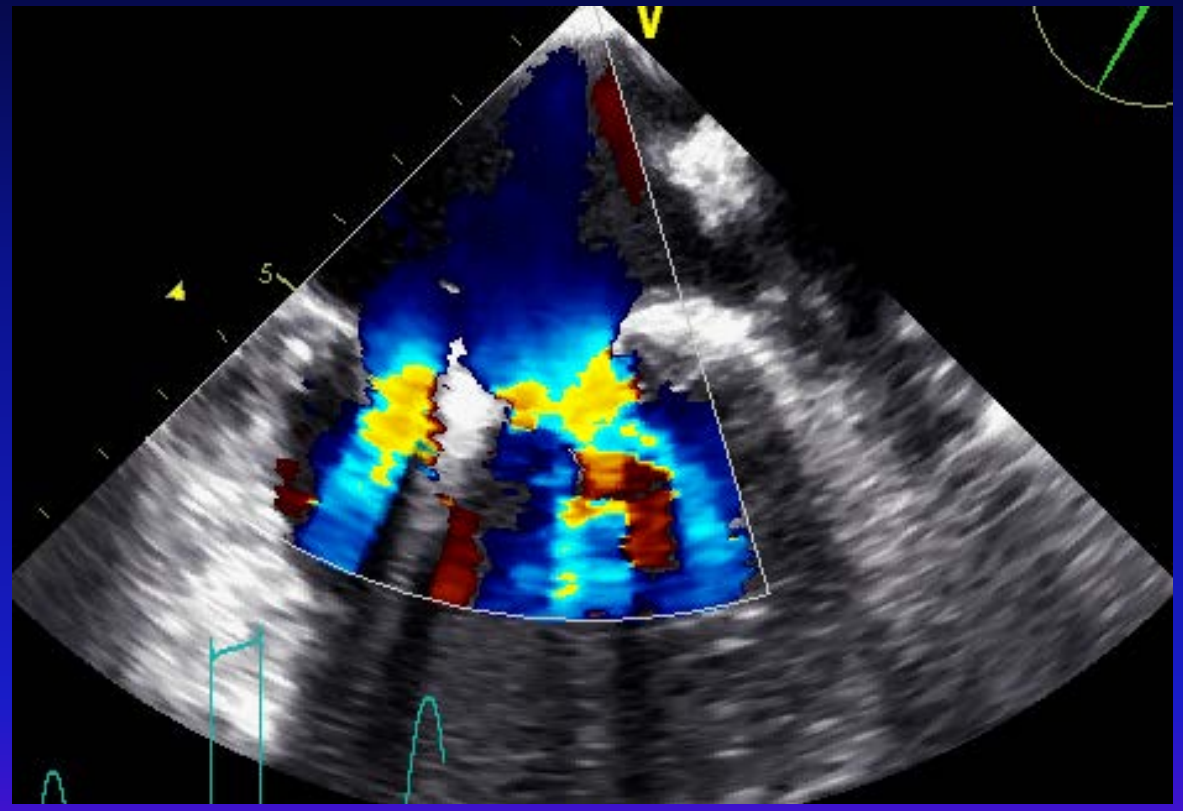

DIA residuo alla rimozione del delivery system

Come si impianta una clip metallica

18. Si rimuove il catetere guida, si effettua compressione in sede di puntura venosa e si mette un punto nel sottocute.

19. La paziente viene svegliata, estubata e trasferita dalla sala di emodinamica in UTIC dove, se non subentrano complicanze, rimarrà per 24 ore, prima di essere trasferita nel reparto di degenza ordinaria.